AMERICAN ACADEMY OF OPHTHALMOLOGY®

Corneal Topography for Intraocular Lens Selection in Refractive Cataract Surgery

So Goto, MD, PhD,[1,2,3] *Naoyuki Maeda, MD, PhD*[1]

The purpose of this review is to evaluate the usefulness of corneal topography to select premium intraocular lenses (IOLs), including aspherical IOLs, toric IOLs, and multifocal IOLs, in refractive cataract surgery. Corneal topography can detect corneal regular astigmatism, corneal irregular astigmatism (higher-order aberrations [HOAs]) including spherical aberration, and corneal shape abnormalities after corneal refractive surgery. Surgeons can explain to the patients with significant corneal HOAs about its effect on postoperative visual function before surgery. Multifocal IOLs should not be selected for such eyes. For eyes with abnormal corneal shape, appropriate IOL power calculation formulae can be applied. In the case of toric IOLs, regular astigmatism and corneal HOAs should be checked. Before implanting an aspheric IOL, it is ideal to confirm spherical aberration of the cornea is not below the normal range. Because corneal HOAs, abnormal corneal shape after corneal refractive surgery, corneal regular astigmatism, and corneal spherical aberration increase postoperative refractive errors and poor vision quality with premium IOLs, corneal topography before cataract surgery is helpful in screening patients who are not appropriate candidates for premium IOLs. *Ophthalmology 2021;128:e142-e152 © 2020 by the American Academy of Ophthalmology*

In the 21st century, the introduction of premium or new technology intraocular lenses (IOLs), such as aspherical IOLs, toric IOLs, and multifocal/extended depth of focus (EDOF) IOLs, has resulted in a paradigm shift in cataract surgery from just treating the disease to optimizing the refractive outcome as refractive surgery. It is now possible to minimize refractive errors and improve the quality of vision without spectacle dependency after surgery. The number of choices for IOLs has expanded, and as a result, planning for cataract surgery has become complicated. Furthermore, there is the risk of patient dissatisfaction after the surgery, even if a surgeon provides technically beautiful surgery.

Corneal topography is considered an essential examination before corneal refractive surgery.[1,2] This is because it enables surgeons to exclude mild ectatic corneal disorders that are contraindicated and undetectable with conventional examinations from the candidates of corneal refractive surgeries.[3,4] Corneal topography has been used preoperatively for the calculation of IOL power and in planning the location and size of the incision in some cases.[5] Corneal topography might also be a powerful screening tool that helps determine the indication or contraindications for premium IOLs before refractive cataract surgery. We review the value of preoperative assessment with corneal topography in the selection of a premium IOL.

Principles of Corneal Topography and Tomography

In general, manual or automated keratometer has been used for taking the keratometric readings (K readings) in the clinic. The keratometer projects a ring light onto the corneal surface. The image created by the reflection of the ring illumination from the tear film on the corneal surface is the first Purkinje-Sanson image and is called the mire (Fig 1A). The radii of the corneal curvature and the axis of astigmatism are determined by analyzing the size and toricity of the mire while keeping the working distance constant and the eye fixed. The keratometer measures only the corneal radii of the front surface and estimates the total corneal power of the anterior and posterior surfaces, not with the true refractive index of the corneal stroma (1.376), but with the keratometric index (1.3375 or 1.3315) based on the assumption that there is a constant ratio between the anterior and posterior corneal curvature. This is called the Gullstrand ratio in the Gullstrand exact schematic eye.[6,7]

The keratometer uses a single mire that provides information on the values at the paracentral zone only (∼3 mm in diameter), whereas a corneal topographer covers a large area of the cornea with a Placido disc that comprises multiple coaxial ring illuminations (Fig 1A).[8,9] Corneal topography provides a color-coded topographic map based on the power across an extensive area of the cornea and topographic indices based on the mires.[10,11] Corneal topography enables us to diagnose corneal shape abnormalities and to evaluate irregular astigmatism or higher-order aberrations (HOAs) qualitatively by the visual inspection of a color-coded map and quantitatively by the topographic indices.[12]

The advantage of a Placido-based corneal topographer is that it uses the same principle as a keratometer for measurement; simulated K readings can be shown as the compatible index of K readings, although these 2 indices are not always interchangeable. Placido-based corneal topography obtains the

Published by Elsevier Inc.
https://doi.org/10.1016/j.ophtha.2020.11.016
ISSN 0161-6420/20

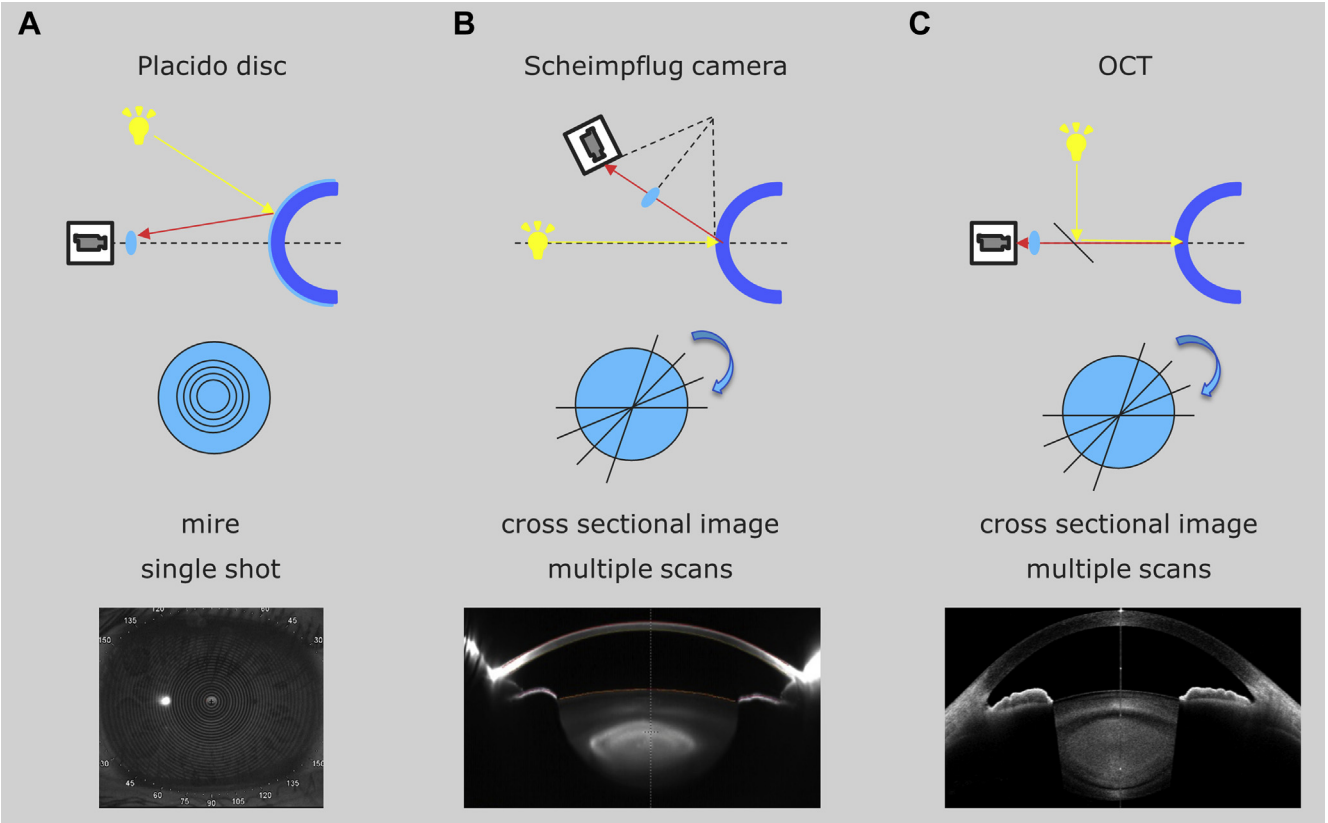

Figure 1. Principles of corneal topography and corneal tomography. **A,** Placido–based corneal topography. **B,** Scheimpflug camera. **C,** OCT.

image created at the precorneal tear film quickly in a single shot, which contributes to the good reproducibility of the data. However, caution should be heeded with the errors associated with changes in the tear film such as dry eye and prior contact examinations.[13]

An aberrometer or wavefront sensor is a device for measuring the ocular HOAs of the eye. Some aberrometers simultaneously measure corneal topography and can determine not only ocular cylinder and ocular HOAs but also corneal cylinder, corneal HOAs, internal cylinder, and internal HOAs (Fig 2).[14] Furthermore, one of the aberrometers can adopt full gradient corneal topography where the illumination was modified from Placido disc to a grid pattern, and it is expected to improve the reproducibility by reducing segmentation errors.[15,16]

Different from corneal topography, corneal tomography uses a series of optical cross-section images of the anterior segment of the eye that are then reconstructed as a 3-dimensional image. The slit-scanning corneal tomographer,[17] the rotating Scheimpflug camera (Fig 3),[18-21] and the anterior segment OCT (Fig 4A and B) are included.[22-27] As the lens of the Scheimpflug camera is tilted to the image plane based on the Scheimpflug principle, the obtained cross-section image has a sharper focus in a wider range, compared with the image that is taken with the usual camera where image plane, lens plane, and subject plane are parallel (Fig 1B). OCT can also provide a sharper cross-section image with less distortion than the Scheimpflug camera using infrared light (Fig 1C). By analyzing the 3-dimensional images of the cornea, the elevation maps and the power maps of the anterior and posterior corneal surfaces, as well as the pachymetric map, can be obtained.

The advantages of corneal tomography over corneal topography are that cylinder and HOAs of the posterior corneal surface and the corneal thickness profile can be obtained in addition to anterior corneal topography. Furthermore, there is less influence of precorneal tear film on the data. However, attention is needed to capture images with good quality and high repeatability because the Scheimpflug camera or OCT requires a longer time to scan multiple images than the Placido disc topographer.

Evaluation of Corneal Irregular Astigmatism

In general, corneal irregular astigmatism has been qualitatively evaluated with the visual inspection of color-coded maps and quantitatively evaluated with the inductive topography/tomography indices. Wavefront technology enabled us not only to quantify lower order aberrations that can be corrected with spectacles (defocus and regular astigmatism) but also to measure HOAs that cannot be corrected with spectacles, including coma, spherical aberration, and other terms with the use of Zernike polynomials (Fig 5). Although the aberrometer analyzes ocular aberrations, we can quantify corneal irregular astigmatism

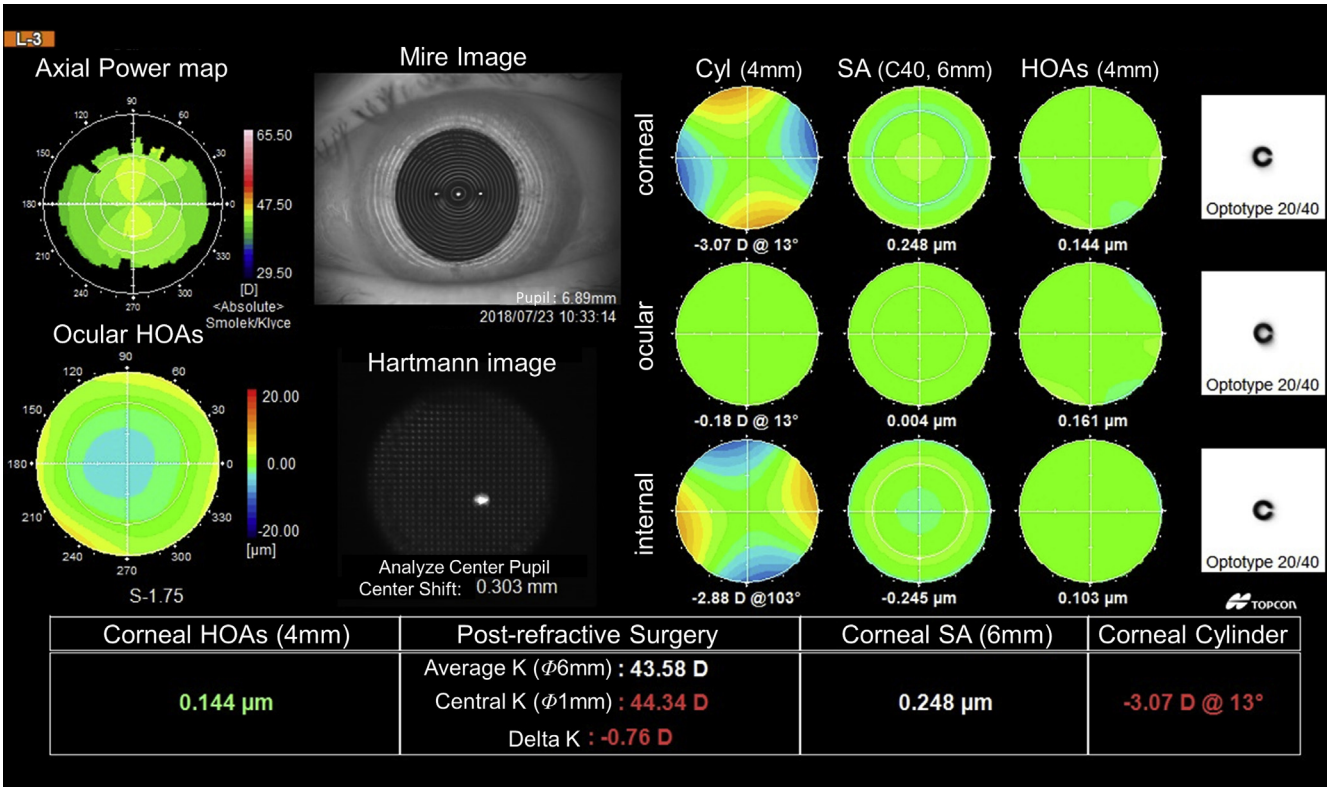

Figure 2. Intraocular lens (IOL) selection map in a Hartmann–Shack aberrometer (KR–1W, Topcon Corp.) after toric IOL implantation. Topographic map reveals with-the-rule (WTR) astigmatism. Total cornea higher-order aberration (0.144 μm) and spherical aberration (0.248 μm) are within normal ranges. The corneal cylinder (−3.07 D @ 13 degrees) was compensated by the internal cylinder (−2.88 D @ 103 degrees), and the misalignment of the toric IOL was zero. D = diopter; HOA = higher-order aberration; SA = spherical aberration.

as corneal HOAs by applying the Zernike expansion to the corneal elevation data.

First, surgeons need to evaluate the corneal irregular astigmatism and the optical quality of the cornea in patients with cataracts to determine the indication for cataract surgery and the selection of IOL. This is because visual recovery after cataract surgery for the eye with irregular corneal astigmatism may not be as good as the surgeon and the patient expected because of the preexisting corneal irregular astigmatism. The surgeon should inform the patient with corneal irregular astigmatism about the partial recovery of vision after surgery. This would be more critical for the multifocal/EDOF and toric IOL candidates. Excellent uncorrected visual acuity cannot be expected in patients with corneal irregular astigmatism.

Routine examinations with a slit-lamp and keratometer are not enough to evaluate corneal irregular astigmatism associated with mild ectatic corneal disorders, mild corneal diseases, and eyes after corneal refractive surgeries and keratoplasty. In addition, the IOL power calculation remains challenging in eyes after corneal transplantation[28] or eyes with keratoconus.[29-31] The surgeon also needs to explain to such patients about the higher risk of postoperative errors from attempted refraction before surgery (Fig 3).

Corneal topography is also helpful in detecting ocular surface diseases, because mires are sensitive to irregularities of the precorneal tear film.[32] K values of poor reproducibility are a leading cause of IOL power calculation prediction errors. In this context, patients with dry eye are considered as high-risk candidates for unsatisfied visual outcome after cataract surgery.[32] Serial measurements of ocular HOAs have indicated that aqueous deficiency or evaporating dry eye may underlie poor or fluctuating vision quality.[33,34] This is one of the reasons why the American Society of Cataract and Refractive Surgery proposed the practical diagnostic ocular surface disorders algorithm to diagnose and treat visually significant ocular surface disorders before performing any refractive surgeries.[35]

In addition to the corneal HOAs, the size and location of the pupil should be within the normal range to avoid postoperative symptoms such as halo, glare, and dysphotopsia. The axis of the cornea does not coincide with the axis of the crystalline lens, and there are some variations in the angle between the corneal axis and crystalline lens even in the normal eyes. One can easily expect the deterioration of visual function due to the tilt and decentration of the IOL relative to the corneal axis, especially when the multifocal IOL was implanted in the eye with a large angle between the corneal and lenticular axis.[36-38] For these reasons, preoperative corneal topography should be performed on all refractive cataract surgery candidates.

Evaluation for Toric Intraocular Lens

Approximately 30% and 10% of patients who have undergone cataract surgery have a preoperative corneal

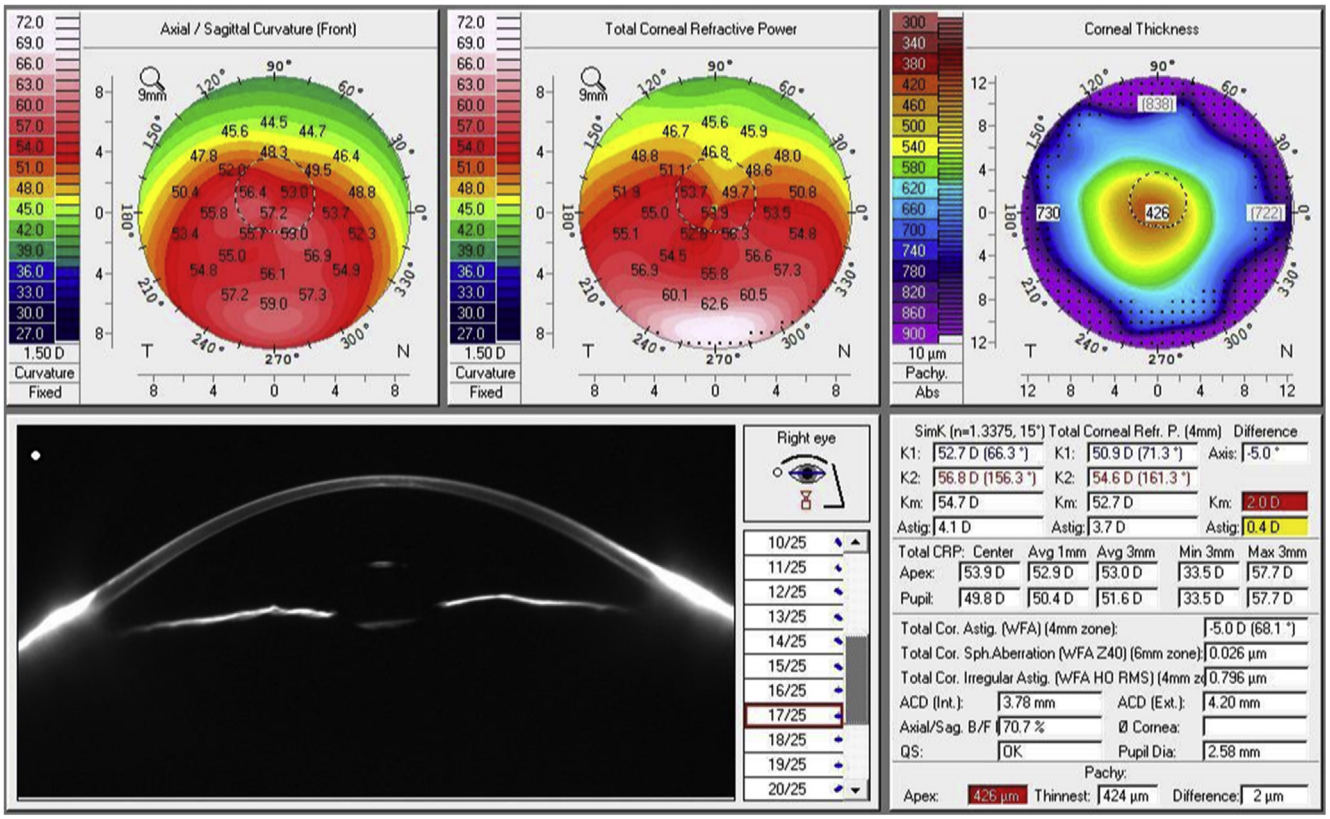

Figure 3. Precataract display in a Scheimpflug camera (Pentacam HR, OCULUS Optikgeräte GmbH) for keratoconus. Axial power map shows localized steepening. Total higher-order aberration (0.796 µm) is high. The multifocal intraocular lens is not recommended with the informed consent for the effects of corneal irregular astigmatism on quality of vision. D = diopter.

astigmatism of 1.00 diopters (D) or higher and 2.00 D or higher, respectively.[39] Toric IOLs offer patients the opportunity to correct corneal regular astigmatism at the time of the cataract surgery and achieve spectacle independence for distance vision or near vision when the eye has no significant irregular astigmatism.

Toric IOLs are generally avoided in the case of keratoconus with significant irregular astigmatism.[40] This is because the quality of vision cannot be guaranteed because of corneal irregular astigmatism, and the astigmatism of toric IOLs will be prominent with the use of the rigid gas permeable lens after surgery. Toric IOL implantation should be considered only in patients who do not plan to wear a rigid gas permeable lens after surgery. On the contrary, toric IOLs have been reported to be effective in patients with mild irregular corneal astigmatism, including keratoconus,[41,42] pellucid marginal degeneration,[43,44] and postkeratoplasty eyes.[28]

The preoperative assessment of corneal topography is critical to exclude irregular corneal astigmatism cases (Fig 3). The corneal topographic map is useful to qualitatively assess whether the cornea has only regular astigmatism (orthogonal and symmetric bowtie pattern) or a certain degree of irregular astigmatism (asymmetric or skewed bowtie pattern). In addition, corneal topographic indices such as simulated K readings, Surface Regularity Index,[11] Fourier analysis,[45,46] and corneal HOAs are helpful in evaluating the regular and irregular astigmatism quantitatively (Figs 2–4).

Posterior corneal astigmatism also exerts errors in astigmatism correction after toric IOL implantation.[47] Although anterior corneal astigmatism tends to shift from with-the-rule (WTR) astigmatism to against-the-rule (ATR) astigmatism with age, posterior corneal astigmatism remains ATR throughout life in many cases.[40] Selecting a toric IOL based on only anterior corneal measurements using a keratometer or Placido-based topographer could lead to an overcorrection in WTR eyes and an undercorrection in ATR eyes.[48] Therefore, Koch et al[49] proposed that in the case of WTR astigmatism, the calculated corneal astigmatism can be decreased by 0.5 D, and in the case of ATR astigmatism, it should be increased by 0.3 D. The Barrett toric calculator, which adjusts the cylindrical power and axis of alignment for the IOL according to a mathematic model of the posterior corneal surface, yields lower astigmatic prediction errors than the Holladay toric calculator, which uses the keratometric cylinder without adjusting the cylinder due to the posterior corneal surface.[50,51] The direct measurement of the total corneal cylinder using the anterior and posterior cylinder from corneal tomography will be expected as an alternative method that does not need the WTR/ATR adjustment.

Because the cataract surgery tends to render both regular and irregular astigmatism neutral, the evaluation of preoperative corneal astigmatism for reducing postoperative astigmatism and the role of toric IOLs in cataract surgery have

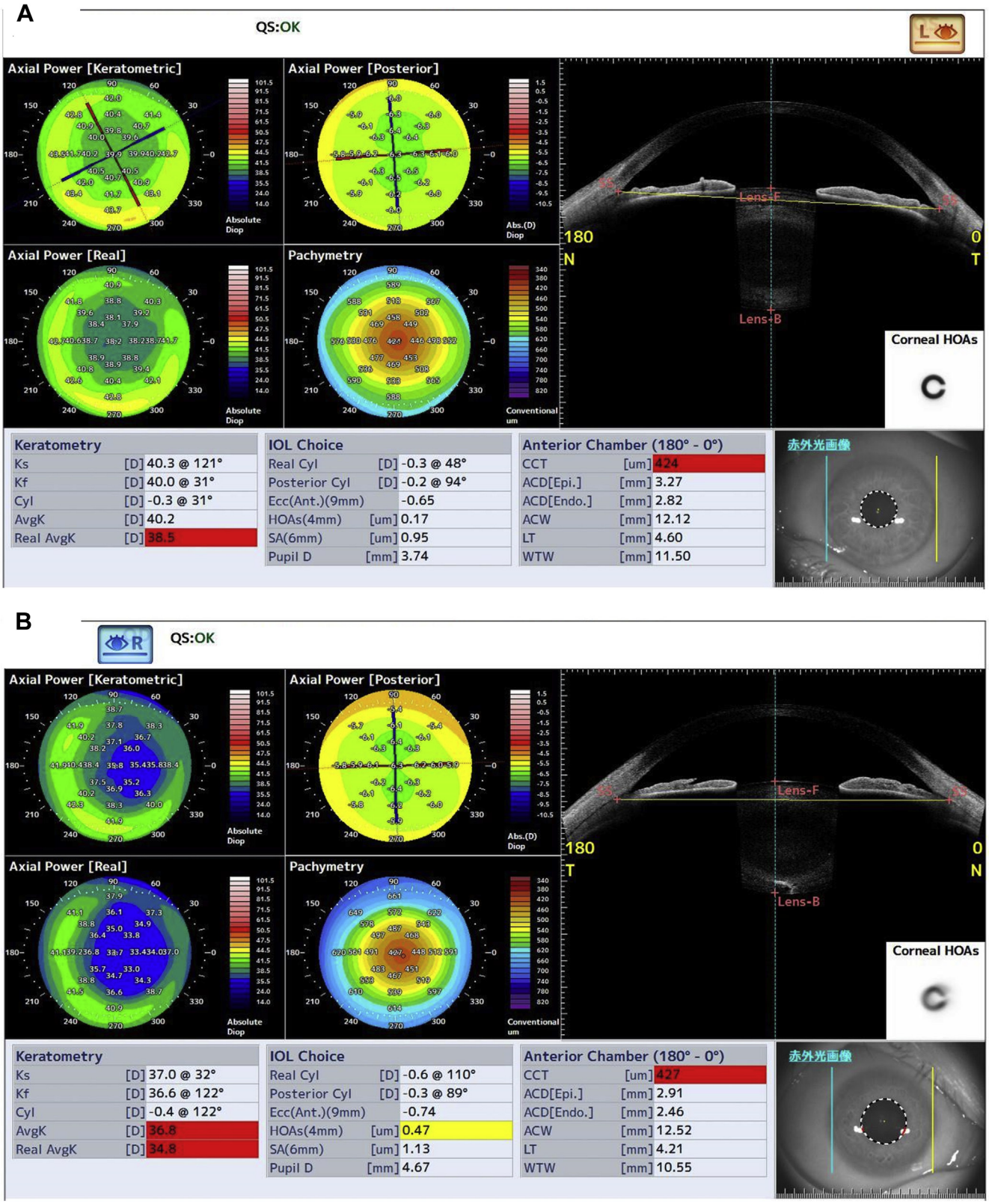

Figure 4. Preoperative cataract display in an anterior-segment OCT (CASIA2, Tomey Corp.) for post-LASIK eye. **A,** Axial power map shows the central flattening, and pachymetric map shows corneal thinning in the center. Total cornea higher-order aberration (HOA, 0.17 μm) is within normal range, and spherical aberration (0.95 μm) is relatively high. Monofocal aspherical intraocular lens (IOL) is recommended with IOL formulas for postmyopic LASIK. **B,** Axial power map indicates the decentered ablation. Total cornea HOA (0.47 μm) is relatively high, and spherical aberration (1.13 μm) is also high. The simulated retinal image of Landolt ring is blurry. The surgeon should consider the effect of corneal HOAs on the preoperative and postoperative visual function. HOA = higher-order aberration; IOL = intraocular lens; SA = spherical aberration.

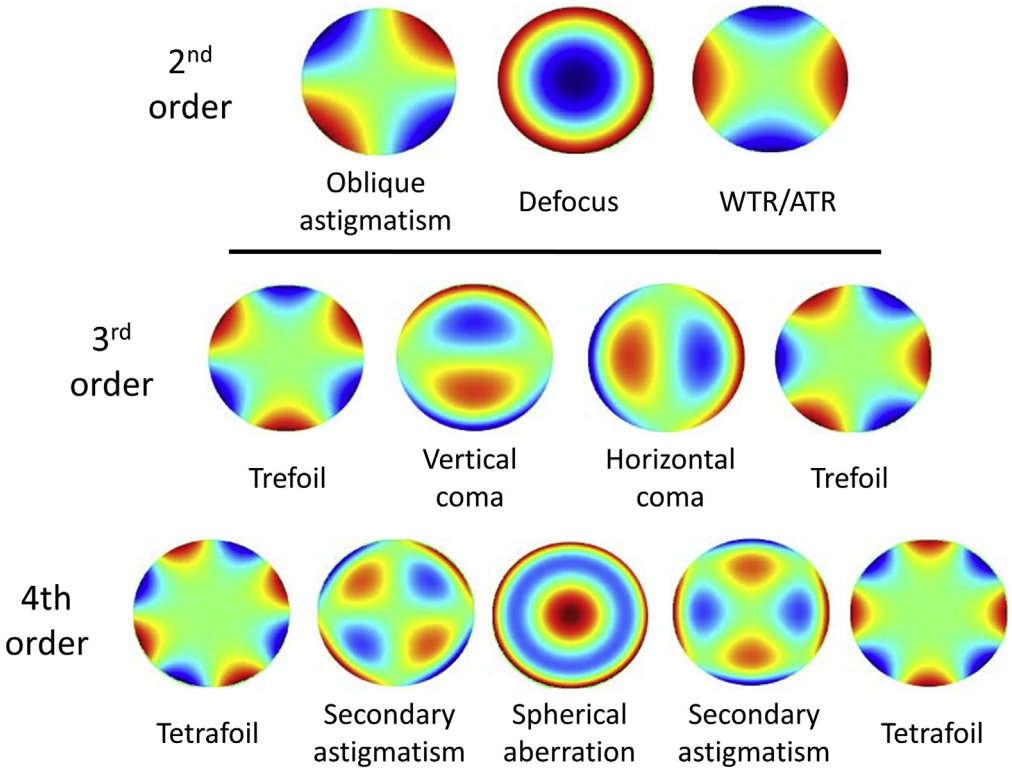

Figure 5. Terms of lower-order aberrations (second) and higher-order aberrations (HOAs, third and fourth) in Zernike polynomials. Because each term is independent in Zernike polynomials, complex wavefront can be quantified separately to these terms. ATR = against-the-rule; WTR = within-the-rule.

become increasingly important in conjunction with the surgical guidance system and the intraoperative aberrometry.[52-55]

Evaluation for Aspherical Intraocular Lens

The aspherical IOL was designed with a fixed amount of negative spherical aberration that is intended to compensate for the average positive spherical aberration of the cornea.[56,57] At an optical zone of 6.0 mm, the spherical aberration of the healthy cornea is approximately +0.27 ± 0.09 μm.[58-60] To leave the ocular spherical aberration at the level of normal young adults (+0.1 μm) or minimize ocular spherical aberration, the aspherical IOL was adjusted by mostly −0.17 to −0.27 μm.

Aspherical IOLs are likely to provide more accurate refractive results than spherical IOLs.[61,62] The quality of vision, especially with respect to contrast sensitivity and mesopic vision, has been improved.[63-65] In most cases of multifocal IOLs, the aspherical optical design is used to reduce the loss of contrast sensitivity due to the increase in spherical aberration by the spherical IOLs in addition to the corneal spherical aberration.[66]

Although the superiority of aspherical IOLs over spherical IOLs remains controversial, 2 systematic reviews with meta-analysis exist that demonstrate that aspheric monofocal IOL implantation results in less ocular spherical aberration and ocular HOAs than spherical IOLs, and that aspherical IOLs can provide better contrast sensitivity than spherical IOLs.[67,68] However, the reduction of total spherical aberration after aspherical IOL implantation may degrade distance-corrected near, intermediate visual acuity, and depth of focus.[69,70]

In eyes with LASIK/advanced surface ablation or radial keratotomy for myopia, corneal spherical aberration tends to increase as the cornea becomes oblate in shape due to central flattening (Fig 4A and B).[71,72] Aspherical IOLs will be more effective than spherical IOLs in such eyes.[73,74] On the other hand, keratoconus and LASIK or advanced surface ablation for hyperopia tend to decrease the spherical aberration.[75] Selecting spherical instead of aspherical IOLs when the cornea has such a negative spherical aberration is reasonable.

Theoretically, aspherical IOLs will work best for eyes with an average range of corneal spherical aberration without the other forms of corneal HOAs. Total corneal HOAs increase with age,[76] but corneal spherical aberration showed no significant change with age.[77-79] Whether or not corneal coma increases with age remains controversial. Therefore, it is ideal not only to check the spherical aberration but also to determine total HOAs with corneal topography or tomography before cataract surgery.

Attention also should be paid to the postoperative tilt and decentration of the aspherical IOL that might induce more coma than those of the spherical IOLs, especially in eyes with pseudoexfoliation syndrome, angle-closure glaucoma, and possible conditions with zonular weakness or severe capsule construction.[80,81]

Evaluation for Multifocal Intraocular Lens and Extended Depth of Focus Intraocular Lens

There have been remarkable advances in the technology of multifocal IOLs,[82,83] and various concepts of multifocal IOLs are available.[84,85] In addition, EDOF IOLs that have a longer depth of field than monofocal IOLs and have less halo and glare than multifocal IOLs are currently available.[86] Both IOLs may increase the risk of reduced contrast sensitivity and photic phenomena such as glare and halo, especially when the eye or the contralateral eye has anterior or posterior segment pathologies besides cataract.[87-89]

It is well known that the increase in corneal HOAs decreases contrast sensitivity.[64,65,90] As explained previously, corneal topography may play an important role in the indication of multifocal/EDOF IOLs by detecting abnormal corneal HOAs associated with mild keratoconus (Fig 3), mild pterygium, or other corneal disorders.[91-93]

Currently, we set the tentative cutoff values for the indication of the multifocal IOL transplantation as less than 0.3 μm in corneal HOAs within a 4-mm diameter, because the blurring effect of 0.5 D defocus theoretically corresponds to the root mean square (μm) value of 0.29 μm for a 4-mm diameter.[94,95] One study found that anterior coma values greater than 0.32 μm might result in intolerable dysphotopsia in the presence of a diffractive multifocal IOL (Hamza I, Aly MG, Hashem KA. Multifocal IOL dissatisfaction in patients with high coma aberrations, Presented at the ASCRS Symposium on Cataract, IOL and Refractive Surgery, San Diego, California, March 25–29, 2011). Although there are no other guidelines regarding the cutoff values of HOAs in the implantation of multifocal IOLs, eyes with abnormal corneal HOAs should be considered as the contraindication,[89] and the routine assessment of abnormal corneal HOAs may be helpful to choose premium IOLs.

Intraocular Lens Power Calculation for Eyes after Refractive Surgery

The IOL power calculation should be performed differently in patients with abnormal corneal shape, including those who have undergone previous corneal refractive surgery such as radial keratotomy,[96] advanced surface ablation, or LASIK.[97-99] If standard IOL power formulae are used for these eyes, a refractive surprise can occur because advanced surface ablation and LASIK alter the Gullstrand ratio, which makes the keratometric index invalid and induces errors in K readings.[100-102] Moreover, if the effective lens position is calculated based on K readings in a particular IOL formula, the effective lens position is often erroneous and results in postoperative refractive errors.[97] Since 2000, more than 30 formulae have been published for eyes after laser refractive surgery; the most recent studies have shown that better refractive outcomes can be achieved if appropriate formulae are selected.[103]

Corneal topography or tomography is useful in identifying the history of myopic or hyperopic corneal laser refractive surgeries through the topographic pattern even if the patient did not state a history of surgery. Also, it allows estimating whether the optical zone is centered or decentered and whether the corneal HOAs are low or high based on the corneal topography or tomography (Fig 4A and B).[104-106] The instantaneous power map is valuable in evaluating the displacement of the optical zone.[105,107]

Table 1. Four Steps in Corneal Topography for Screening before Cataract Surgery

Step 1: Corneal higher-order aberration (HOAs)
If corneal HOA is abnormal, multifocal or toric intraocular lens (IOLs) should be avoided and informed consent should be conducted for irregular astigmatism.
Step 2: Topographic pattern
If topographic pattern indicates postrefractive surgery, special IOL formula should be used in place of routinely used formula.
Step 3: Corneal astigmatism
If topographic pattern indicates regular astigmatism without asymmetry for both surfaces, toric IOL can be considered.
Step 4: Corneal spherical aberration
If corneal spherical aberration shows negative values, spherical IOLs should be considered.

When corneal topography screening reveals eyes with normal corneal shape, K readings with an optical biometer or keratometer should be used for the IOL power calculation. Keratometry-style values, such as simulated K-readings in Placido-based corneal topography, Scheimpflug camera, and anterior segment OCT, can be used as alternatives for K readings as the corneal power in some IOL formulae. Some of these indices are not always interchangeable to K readings and sometimes lead to less accurate refractive outcomes in normal eyes with 2-variable vergence formulas or third-generation IOL power formulae, such as Holladay 1, SRK/T, and Hoffer Q.[108,109]

For the eyes with an abnormal corneal shape, K readings are not always available. Moreover, they do not always minimize postoperative refractive errors, especially when there is a considerable disparity between corneal power at the center and the paracentral area.[110] In such cases, the corneal power calculated by the ray tracing based on Snell's law using both anterior and posterior curvatures may be one of the theoretical alternatives to K readings.[111,112]

Some investigators reported good refractive outcomes for eyes with a history of refractive surgery using OCT to calculate IOL power.[111-114] However, corneal power calculated by ray tracing with a normal corneal shape is lower than K readings with the keratometric index by approximately 0.5 to 0.9 D.[108,109,115] Therefore, these values should not be used without modification for eyes with normal corneas in most of the IOL power formulae. Because existing vergence IOL power calculation formulas were developed in the 1990s, these are completely compatible with keratometry values.

In conclusion, with the increasing use of technically advanced IOLs, systematic preoperative assessment with corneal topography is critical for preventing postoperative refractive errors and poor vision quality. Patients who are not appropriate candidates for premium IOLs due to abnormal corneal conditions, such as irregular corneal astigmatism, negative spherical aberration, and proportional abnormalities

in power or astigmatism between the anterior and posterior corneal surface, should be identified before surgery.

To ensure efficient screening of corneal topography in candidates of cataract surgery, we propose 4 steps for the interpretation of the results (Table 1). First, check for corneal irregular astigmatism. If corneal HOAs are high, informed consent should be performed for insufficient visual recovery due to corneal irregular astigmatism and the higher risk of refractive error after surgery. Multifocal IOLs should be avoided. Second, check the abnormal corneal shape after laser refractive surgery. In cases with a topographic pattern after refractive surgery, confirm the surgical history with the patient and use the correct IOL formula for postrefractive surgery. Third, check for regular astigmatism and make sure the bowtie pattern is not asymmetric or skewed. Fourth, check for corneal spherical aberration and consider the selection of the spherical or aspherical IOLs based on the corneal spherical aberration.

Footnotes and Disclosures

Originally received: February 2, 2020.
Final revision: October 26, 2020.
Accepted: November 13, 2020.
Available online: November 19, 2020. Manuscript no. D-20-00200.

[1] Department of Ophthalmology, Osaka University Graduate School of Medicine, Yamadaoka, Suita, Osaka, Japan.

[2] Department of Ophthalmology, National Hospital Organization, Tokyo Medical Center, Higashigaoka, Meguro-ku, Tokyo, Japan.

[3] School of Optometry, University of California, Berkeley, California.

Disclosure(s):
All authors have completed and submitted the ICMJE disclosures form.
The author(s) have made the following disclosure(s): N.M.: Grants − Topcon, during the conduct of the study; Personal fees − Alcon, Bausch + Lomb, HOYA, Otsuka, Santen, Senjyu, Tomey, Menicon, Pfizer, outside the submitted work.

HUMAN SUBJECTS: IRB/Ethics Committee ruled that approval was not required for this study. All research adhered to the tenets of the Declaration of Helsinki. The requirement for informed consent was waived because of the retrospective nature of the study.

No animal subjects were used in this study.

Author Contributions

Conception and design: Goto, Maeda

Data collection: Goto, Maeda

Analysis and interpretation: Goto, Maeda

Obtained funding: Maeda; Study was performed as part of regular employment duties at Osaka University. No additional funding was provided.

Overall responsibility: Goto, Maeda

Abbreviations and Acronyms:
ATR = against-the-rule; **D** = diopters; **EDOF** = extended depth of focus; **HOA** = higher-order aberration; **IOL** = intraocular lens; **WTR** = with-the-rule.

Keywords:
Corneal topography, Higher-order aberration, Irregular astigmatism, Premium intraocular lens, Spherical aberration.

Correspondence:
Naoyuki Maeda, MD, PhD, Department of Ophthalmology, Osaka University Graduate School of Medicine, Room E7, Yamadaoka 2-2, Suita, Osaka, 565-0871, Japan. E-mail: nmaeda@ophthal.med.osaka-u.ac.jp.

References

1. Wilson SE, Klyce SD. Screening for corneal topographic abnormalities before refractive surgery. *Ophthalmology*. 1994;101:147−152.
2. Randleman JB, Woodward M, Lynn MJ, Stulting RD. Risk assessment for ectasia after corneal refractive surgery. *Ophthalmology*. 2008;115:37−50.
3. Maeda N, Klyce SD, Smolek MK, Thompson HW. Automated keratoconus screening with corneal topography analysis. *Investig Ophthalmol Vis Sci*. 1994;35:2749−2757.
4. Kalin S, Maeda N, Klyce SD, et al. Automated topographic screening for keratoconus in refractive surgery candidates. *CLAO J*. 1996;22:164−167.
5. McQueen BR, Martinez CE, Klyce SD. Corneal topography in cataract surgery. *Curr Opin Ophthalmol*. 1997;8:22−28.
6. Gullstrand A. *Einfihrung in die Methoden der Dioptrik des Auges des Menschen*. Leipzig: Verlag von S. Hirzel; 1911.
7. Olsen T. On the calculation of power from curvature of the cornea. *Br J Ophthalmol*. 1986;70:152−154.
8. Rowsey JJ, Reynolds AE, Brown R. Corneal topography, Corneascope. *Arch Ophthalmol*. 1981;99:1093−1100.
9. Klyce SD. Computer-assisted corneal topography. High-resolution graphic presentation and analysis of keratoscopy. *Invest Ophthalmol Vis Sci*. 1984;25:1426−1435.
10. Gormley DJ, Gersten M, Koplin RS, Lubkin V. Corneal modeling. *Cornea*. 1988;7:30−35.
11. Wilson SE, Klyce SD. Quantitative descriptors of corneal topography: a clinical study. *Arch Ophthalmol*. 1991;109:349−353.
12. Shiotani Y, Maeda N, Inoue T, et al. Comparison of topographic indices that correlate with visual acuity in videokeratography. *Ophthalmology*. 2000;107:559−564.
13. American Academy of Ophthalmology. Corneal topography. *Ophthalmology*. 1999;106:1628−1638.
14. Maeda N. Topcon KR-1W. In: Wang M, ed. *Corneal Topography: A Guide for Clinical Application in the Wavefront Era*. 2nd ed. Thorofare, NJ: SLACK Inc.; 2012:191−197.
15. Prakash G, Jhanji V, Srivastava D, et al. Single session, intraobserver repeatability of an advanced new generation Hartmann−Shack Aberrometer in refractive surgery candidates. *J Ophthalmic Vis Res*. 2015;10:498−501.
16. Schallhorn SC, Venter JA, Hannan SJ, Hettinger KA. Wavefront-guided photorefractive keratectomy with the use of a new Hartmann−Shack aberrometer in patients with myopia and compound myopic astigmatism. *J Ophthalmol*. 2015;2015:514837.
17. Yaylali V, Kaufman SC, Thompson HW. Corneal thickness measurements with the Orbscan Topography System and ultrasonic pachymetry. *J Cataract Refract Surg*. 1997;23:1345−1350.

18. Lackner B, Schmidinger G, Pieh S, et al. Repeatability and reproducibility of central corneal thickness measurement with Pentacam, Orbscan, and ultrasound. *Optom Vis Sci*. 2005;82:892−899.
19. Barkana Y, Gerber Y, Elbaz U, et al. Central corneal thickness measurement with the Pentacam Scheimpflug system, optical low-coherence reflectometry pachymeter, and ultrasound pachymetry. *J Cataract Refract Surg*. 2005;31:1729−1735.
20. Crawford AZ, Patel DV, Mcghee CNJ. Comparison and repeatability of keratometric and corneal power measurements obtained by Orbscan II, Pentacam, and Galilei corneal tomography systems. *Am J Ophthalmol*. 2013;156:53−60.
21. Huang J, Ding X, Savini G, et al. A comparison between Scheimpflug imaging and optical coherence tomography in measuring corneal thickness. *Ophthalmology*. 2013;120:1951−1958.
22. Muscat S, McKay N, Parks S, et al. Repeatability and reproducibility of corneal thickness measurements by optical coherence tomography. *Investig Ophthalmol Vis Sci*. 2002;43:1791−1795.
23. Li Y, Shekhar R, Huang D. Corneal pachymetry mapping with high-speed optical coherence tomography. *Ophthalmology*. 2006;113:792−799.e2.
24. Yasuno Y, Madjarova VD, Makita S, et al. Three-dimensional and high-speed swept-source optical coherence tomography for in vivo investigation of human anterior eye segments. *Opt Express*. 2005;13:10652.
25. Fukuda S, Kawana K, Yasuno Y, Oshika T. Anterior ocular biometry using 3-dimensional optical coherence tomography. *Ophthalmology*. 2009;116:882−889.
26. Maeda N. Optical coherence tomography for corneal diseases. *Eye Contact Lens*. 2010;36:254−259.
27. Nakagawa T, Maeda N, Higashiura R, et al. Corneal topographic analysis in patients with keratoconus using 3-dimensional anterior segment optical coherence tomography. *J Cataract Refract Surg*. 2011;37:1871−1878.
28. Wade M, Steinert RF, Garg S, et al. Results of toric intraocular lenses for post-penetrating keratoplasty astigmatism. *Ophthalmology*. 2014;121:771−777.
29. Thebpatiphat N, Hammersmith KM, Rapuano CJ, et al. Cataract surgery in keratoconus. *Eye Contact Lens*. 2007;33:244−246.
30. Kamiya K, Iijima K, Nobuyuki S, et al. Predictability of intraocular lens power calculation for cataract with keratoconus: a multicenter study. *Sci Rep*. 2018;8:1−7.
31. Wang KM, Jun AS, Ladas JG, et al. Accuracy of intraocular lens formulas in eyes with keratoconus. *Am J Ophthalmol*. 2020;212:26−33.
32. Gupta PK, Drinkwater OJ, Vandusen KW, et al. Prevalence of ocular surface dysfunction in patients presenting for cataract surgery evaluation. *J Cataract Refract Surg*. 2018;44:1090−1096.
33. Montés-Micó R, Cáliz A, Alió JL. Wavefront analysis of higher order aberrations in dry eye patients. *J Refract Surg*. 2004;20:243−247.
34. Koh S, Maeda N, Hirohara Y, et al. Serial measurements of higher-order aberrations after blinking in patients with dry eye. *Investig Ophthalmol Vis Sci*. 2008;49:133−138.
35. Starr CE, Gupta PK, Farid M, et al. An algorithm for the preoperative diagnosis and treatment of ocular surface disorders. *J Cataract Refract Surg*. 2019;45:669−684.
36. Prakash G, Prakash DR, Agarwal A, et al. Predictive factor and kappa angle analysis for visual satisfactions in patients with multifocal IOL implantation. *Eye*. 2011;25:1187−1193.
37. Park CY, Oh SY, Chuck RS. Measurement of angle kappa and centration in refractive surgery. *Curr Opin Ophthalmol*. 2012;23:269−275.
38. Qi Y, Lin J, Leng L, et al. Role of angle κ in visual quality in patients with a trifocal diffractive intraocular lens. *J Cataract Refract Surg*. 2018;44:949−954.
39. Hoffmann PC, Hütz WW. Analysis of biometry and prevalence data for corneal astigmatism in 23 239 eyes. *J Cataract Refract Surg*. 2010;36:1479−1485.
40. Visser N, Bauer NJC, Nuijts RMMA. Toric intraocular lenses: Historical overview, patient selection, IOL calculation, surgical techniques, clinical outcomes, and complications. *J Cataract Refract Surg*. 2013;39:624−637.
41. Visser N, Gast STJM, Bauer NJC, Nuijts RMMA. Cataract surgery with toric intraocular lens implantation in keratoconus: a case report. *Cornea*. 2011;30:720−723.
42. Alió JL, Peña-García P, Guliyeva FA, et al. MICS with toric intraocular lenses in keratoconus: outcomes and predictability analysis of postoperative refraction. *Br J Ophthalmol*. 2014;98:365−370.
43. Luck J. Customized ultra-high-power toric intraocular lens implantation for pellucid marginal degeneration and cataract. *J Cataract Refract Surg*. 2010;36:1235−1238.
44. Balestrazzi A, Baiocchi S, Balestrazzi A, et al. Mini-incision cataract surgery and toric lens implantation for the reduction of high myopic astigmatism in patients with pellucid marginal degeneration. *Eye*. 2015;29:637−642.
45. Oshika T, Tomidokoro A, Maruo K, et al. Quantitative evaluation of irregular astigmatism by Fourier series harmonic analysis of videokeratography data. *Investig Ophthalmol Vis Sci*. 1998;39:5−9.
46. Tanabe T, Tomidokoro A, Samejima T, et al. Corneal regular and irregular astigmatism assessed by Fourier analysis of videokeratography data in normal and pathologic eyes. *Ophthalmology*. 2004;111:752−757.
47. Savini G, Næser K. An analysis of the factors influencing the residual refractive astigmatism after cataract surgery with toric intraocular lenses. *Investig Ophthalmol Vis Sci*. 2015;56:827−835.
48. Koch DD, Ali SF, Weikert MP, et al. Contribution of posterior corneal astigmatism to total corneal astigmatism. *J Cataract Refract Surg*. 2012;38:2080−2087.
49. Koch DD, Jenkins RB, Weikert MP, et al. Correcting astigmatism with toric intraocular lenses: effect of posterior corneal astigmatism. *J Cataract Refract Surg*. 2013;39:1803−1809.
50. Abulafia A, Barrett GD, Kleinmann G, et al. Prediction of refractive outcomes with toric intraocular lens implantation. *J Cataract Refract Surg*. 2015;41:936−944.
51. Ferreira TB, Ribeiro P, Ribeiro FJ, O'Neill JG. Comparison of astigmatic prediction errors associated with new calculation methods for toric intraocular lenses. *J Cataract Refract Surg*. 2017;43:340−347.
52. Suzuki A, Maeda N, Watanabe H, et al. Using a reference point and videokeratography for intraoperative identification of astigmatism axis. *J Cataract Refract Surg*. 1997;23:1491−1495.
53. Ianchulev T, Hoffer KJ, Yoo SH, et al. Intraoperative refractive biometry for predicting intraocular lens power calculation after prior myopic refractive surgery. *Ophthalmology*. 2014;121:56−60.
54. Hura AS, Osher RH. Comparing the Zeiss Callisto eye and the Alcon Verion image guided system toric lens alignment technologies. *J Refract Surg*. 2017;33:482−487.
55. Solomon JD, Ladas J. Toric outcomes: computer-assisted registration versus intraoperative aberrometry. *J Cataract Refract Surg*. 2017;43:498−504.

56. Holladay JT, Piers PA, Koranyi G, et al. A new intraocular lens design to reduce spherical aberration of pseudophakic eyes. *J Refract Surg*. 2002;18:683−691.
57. Packer M, Fine IH, Hoffman RS, Piers PA. Prospective randomized trial of an anterior surface modified prolate intraocular lens. *J Refract Surg*. 2002;18:692−696.
58. Wang L, Dai E, Koch DD, Nathoo A. Optical aberrations of the human anterior cornea. *J Cataract Refract Surg*. 2003;29, 1524−1521.
59. Beiko GHH, Haigis W, Steinmueller A. Distribution of corneal spherical aberration in a comprehensive ophthalmology practice and whether keratometry can predict aberration values. *J Cataract Refract Surg*. 2007;33:845−858.
60. Nemeth G, Hassan Z, Szalai E, et al. Analysis of age dependence of the anterior and posterior cornea with Scheimpflug imaging. *J Refract Surg*. 2013;29:326−331.
61. Bellucci R, Morselli S. Comparison of wavefront aberrations and optical quality of eyes implanted with five different intraocular lenses. *J Refract Surg*. 2004;20:297−306.
62. Savini G, Hoffer KJ, Barboni P. Influence of corneal asphericity on the refractive outcome of intraocular lens implantation in cataract surgery. *J Cataract Refract Surg*. 2015;41:785−789.
63. Marcos S, Barbero S, Jiménez-Alfaro I. Optical quality and depth-of-field of eyes implanted with spherical and aspheric intraocular lenses. *J Refract Surg*. 2005;21:223−235.
64. Rocha KM, Soriano ES, Chalita MR, et al. Wavefront analysis and contrast sensitivity of aspheric and spherical intraocular lenses: a randomized prospective study. *Am J Ophthalmol*. 2006;142:750−756.
65. Kasper T, Bühren J, Kohnen T. Visual performance of aspherical and spherical intraocular lenses: intraindividual comparison of visual acuity, contrast sensitivity, and higher-order aberrations. *J Cataract Refract Surg*. 2006;32: 2022−2029.
66. Terwee T, Weeber H, Van Der Mooren M, Piers P. Visualization of the retinal image in an eye model with spherical and aspheric, diffractive, and refractive multifocal intraocular lenses. *J Refract Surg*. 2008;24:223−232.
67. Schuster A, Tesarz J, Vossmerbaeumer U. The impact on vision of aspheric to spherical monofocal intraocular lenses in cataract surgery: a systematic review with meta-analysis. *Ophthalmology*. 2013;120:2166−2175.
68. Schuster A, Tesarz J, Vossmerbaeumer U. Ocular wavefront analysis of aspheric compared with spherical monofocal intraocular lenses in cataract surgery: systematic review with metaanalysis. *J Cataract Refract Surg*. 2015;41:1088−1097.
69. Rocha KM, Soriano ES, Chamon W, et al. Spherical aberration and depth of focus in eyes implanted with aspheric and spherical intraocular lenses. A prospective randomized study. *Ophthalmology*. 2007;114:2050−2054.
70. Nanavaty MA, Spalton DJ, Boyce J, et al. Wavefront aberrations, depth of focus, and contrast sensitivity with aspheric and spherical intraocular lenses: fellow-eye study. *J Cataract Refract Surg*. 2009;35:663−671.
71. Yoon G, MacRae S, Williams DR, Cox IG. Causes of spherical aberration induced by laser refractive surgery. *J Cataract Refract Surg*. 2005;31:127−135.
72. Bottos KM, Leite MT, Aventura-Isidro M, et al. Corneal asphericity and spherical aberration after refractive surgery. *J Cataract Refract Surg*. 2011;37:1109−1115.
73. Alfonso JF, Madrid-Costa D, Poo-López A, Montés-Micó R. Visual quality after diffractive intraocular lens implantation in eyes with previous myopic laser in situ keratomileusis. *J Cataract Refract Surg*. 2008;34:1848−1854.
74. Fernández-Vega L, Madrid-Costa D, Alfonso JF, et al. Optical and visual performance of diffractive intraocular lens implantation after myopic laser in situ keratomileusis. *J Cataract Refract Surg*. 2009;35:825−832.
75. Llorente L, Barbero S, Merayo J, Marcos S. Total and corneal optical aberrations induced by laser in situ keratomileusis for hyperopia. *J Refract Surg*. 2004;20:203−216.
76. Oshika T, Klyce SD, Applegate RA, Howland HC. Changes in corneal wavefront aberrations with aging. *Invest Ophthalmol Vis Sci*. 1999;40:1351−1355.
77. Amano S, Amano Y, Yamagami S, et al. Age-related changes in corneal and ocular higher-order wavefront aberrations. *Am J Ophthalmol*. 2004;137:988−992.
78. Fujikado T, Kuroda T, Ninomiya S, et al. Age-related changes in ocular and corneal aberrations. *Am J Ophthalmol*. 2004;138:143−146.
79. Namba H, Kawasaki R, Sugano A, et al. Age-related changes in ocular aberrations and the Yamagata Study (Funagata). *Cornea*. 2017;36:S34−S40.
80. Taketani F, Matuura T, Yukawa E, Hara Y. Influence of intraocular lens tilt and decentration on wavefront aberrations. *J Cataract Refract Surg*. 2004;30:2158−2162.
81. Baumeister M, Bühren J, Kohnen T. Tilt and decentration of spherical and aspheric intraocular lenses: effect on higher-order aberrations. *J Cataract Refract Surg*. 2009;35: 1006−1012.
82. Javitt JC, Steinert RF. Cataract extraction with multifocal intraocular lens implantation: a multinational clinical trial evaluating clinical, functional, and quality-of-life outcomes. *Ophthalmology*. 2000;107:2040−2048.
83. Cillino S, Casuccio A, Di Pace F, et al. One-year outcomes with new-generation multifocal intraocular lenses. *Ophthalmology*. 2008;115:1508−1516.
84. De Vries NE, Nuijts RMMA. Multifocal intraocular lenses in cataract surgery: literature review of benefits and side effects. *J Cataract Refract Surg*. 2013;39:268−278.
85. Rosen E, Alió JL, Dick HB, et al. Efficacy and safety of multifocal intraocular lenses following cataract and refractive lens exchange: metaanalysis of peer-reviewed publications. *J Cataract Refract Surg*. 2016;42:310−328.
86. Pedrotti E, Bruni E, Bonacci E, et al. Comparative analysis of the clinical outcomes with a monofocal and an extended range of vision intraocular lens. *J Refract Surg*. 2016;32: 436−442.
87. Woodward MA, Randleman JB, Stulting RD. Dissatisfaction after multifocal intraocular lens implantation. *J Cataract Refract Surg*. 2009;35:992−997.
88. De Vries NE, Webers CAB, Touwslager WRH, et al. Dissatisfaction after implantation of multifocal intraocular lenses. *J Cataract Refract Surg*. 2011;37:859−865.
89. Braga-Mele R, Chang D, Dewey S, et al. Multifocal intraocular lenses: relative indications and contraindications for implantation. *J Cataract Refract Surg*. 2014;40:313−322.
90. McLellan JS, Marcos S, Burns SA. Age-related changes in monochromatic wave aberrations of the human eye. *Investig Ophthalmol Vis Sci*. 2001;42:1390−1395.
91. Tomidokoro A, Miyata K, Sakaguchi Y, et al. Effects of pterygium on corneal spherical power and astigmatism. *Ophthalmology*. 2000;107:1568−1571.
92. Alió JL, Shabayek MH. Corneal higher order aberrations: a method to grade keratoconus. *J Refract Surg*. 2006;22:539−545.
93. Maeno S, Koh S, Renato Ambrósio J, Nishida K. Underestimated corneal abnormalities prior to cataract surgery at university hospital settings. *J Cataract Refract Surg*. 2020: 1−9.

94. Maeda N. Assessment of corneal optical quality for premium IOLs with Pentacam. *Highlights Ophthalmol*. 2011;39:2–5.
95. Maeda N, lto M. Screening cataract surgery candidates with corneal topographer. In: Bissen-Miyajima H, Koch DD, Weikert MP, eds. *Cataract Surgery: Maximising Outcomes Through Research.* Tokyo: Springer Japan; 2014:25–33.
96. Geggel HS. Intraocular lens power selection after radial keratotomy: topography, manual, and IOL master keratometry results using Haigis formulas. *Ophthalmology*. 2015;122:897–902.
97. Aramberri J. Intraocular lens power calculation after corneal refractive surgery: Double-K method. *J Cataract Refract Surg*. 2003;29:2063–2068.
98. Savini G, Barboni P, Zanini M. Intraocular lens power calculation after myopic refractive surgery: theoretical comparison of different methods. *Ophthalmology*. 2006;113:1271–1282.
99. McCarthy M, Gavanski GM, Paton KE, Holland SP. Intraocular lens power calculations after myopic laser refractive surgery: a comparison of methods in 173 eyes. *Ophthalmology*. 2011;118:940–944.
100. Hamilton DR, Hardten DR. Cataract surgery in patients with prior refractive surgery. *Curr Opin Ophthalmol*. 2003;14:44–53.
101. Seitz B, Langenbucher A, Nguyen NX, et al. Underestimation of intraocular lens power for cataract surgery after myopic photorefractive keratectomy. *Ophthalmology*. 1999;106:693–702.
102. Saiki M, Negishi K, Kato N, et al. Modified double-K method for intraocular lens power calculation after excimer laser corneal refractive surgery. *J Cataract Refract Surg*. 2013;39:556–562.
103. Savini G, Hoffer KJ. Intraocular lens power calculation in eyes with previous corneal refractive surgery. *Eye Vis*. 2018;5:1–10.
104. Oshika T, Klyce SD, Applegate RA, et al. Comparison of corneal wavefront aberrations after photorefractive keratectomy and laser in situ keratomileusis. *Am J Ophthalmol*. 1999;127:1–7.
105. Mrochen M, Kaemmerer M, Mierdel P, Seiler T. Increased higher-order optical aberrations after laser refractive surgery: a problem of subclinical decentration. *J Cataract Refract Surg*. 2001;27:362–369.
106. Holladay JT, Janes JA. Topographic changes in corneal asphericity and effective optical zone after laser in situ keratomileusis. *J Cataract Refract Surg*. 2002;28:942–947.
107. Azar DT, Yeh PC. Corneal topographic evaluation of decentration in photorefractive keratectomy: treatment displacement vs intraoperative drift. *Am J Ophthalmol*. 1997;124:312–320.
108. Savini G, Barboni P, Carbonelli M, Hoffer KJ. Comparison of methods to measure corneal power for intraocular lens power calculation using a rotating Scheimpflug camera. *J Cataract Refract Surg*. 2012;39:598–604.
109. Whang WJ, Byun YS, Joo CK. Comparison of refractive outcomes using five devices for the assessment of preoperative corneal power. *Clin Exp Ophthalmol*. 2012;40:425–432.
110. Maeda N, Klyce SD, Smolek M, McDonald M. Disparity between keratometry-style readings and corneal power within the pupil after refractive surgery for myopia. *Cornea*. 1997;16:517–524.
111. Tang M, Li Y, Huang D. An intraocular lens power calculation formula based on optical coherence tomography: a pilot study. *J Refract Surg*. 2010;26:430–437.
112. Minami K, Kataoka Y, Matsunaga J, et al. Ray-tracing intraocular lens power calculation using anterior segment optical coherence tomography measurements. *J Cataract Refract Surg*. 2012;38:1758–1763.
113. Fram NR, Masket S, Wang L. Comparison of intraoperative aberrometry, OCT-based IOL formula, Haigis-L, and Masket formulae for IOL power calculation after laser vision correction. *Ophthalmology*. 2015;122:1096–1101.
114. Wang L, Tang M, Huang D, et al. Comparison of newer intraocular lens power calculation methods for eyes after corneal refractive surgery. *Ophthalmology*. 2015;122:2443–2449.
115. Wang Q, Hua Y, Savini G, et al. Corneal power measurement obtained by Fourier-domain optical coherence tomography: repeatability, reproducibility, and comparison with Scheimpflug and automated keratometry measurements. *Cornea*. 2015;34:1266–1271.