Rotational Stability of Toric Capsular Bag–Fixated Intraocular Lenses in Duet Procedure for Reversible Trifocality

ISABELLA D. BAUR, GERD U. AUFFARTH, MAXIMILIAN K. KÖPPE, GRZEGORZ ŁABUZ, AND RAMIN KHORAMNIA

• PURPOSE: To evaluate the long-term rotational stability of capsular bag–fixated toric intraocular lenses (IOLs) in polypseudophakic eyes of patients who underwent duet procedure for reversible trifocality.

• DESIGN: Retrospective interventional case series.

• METHODS: We included 34 eyes of 20 patients who underwent duet procedure with implantation of a monofocal toric IOL (RayOne toric, Hoya XY1AT, or a Tecnis ZCT800) into the capsular bag and a trifocal-diffractive Sulcoflex IOL into the ciliary sulcus. All toric IOLs were implanted with image-guided navigation. The manifest refraction and uncorrected and distance corrected visual acuity at far, intermediate, and near distance were measured. The position of the axis of the toric IOL was determined with the Pentacam device (Oculus GmbH) by evaluating retroillumination images. The results were compared with the preoperatively planned axis position.

• RESULTS: The median follow-up was 27 months. The spherical equivalent of manifest refraction was –0.04 ± 0.34 diopters (D) postoperatively, and the refractive cylinder was –0.14 ± 0.22 D on average. Binocular uncorrected and corrected distance visual acuity were 0.05 ± 0.11 logMAR and 0.02 ± 0.09 logMAR, respectively. The mean deviation from the calculated cylinder axis was 3.8° ± 3.5° with a median of 2.8° and a maximum deviation of 15.0°. Ninety-four percent of all eyes showed a deviation of less than 10°.

• CONCLUSIONS: The long-term axial alignment of capsular bag–fixated toric IOLs in polypseudophakic eyes was comparable to the results reported for single implantation of toric IOLs. The polypseudophakic approach did not affect the rotational stability of capsular bag–fixated IOLs. (Am J Ophthalmol 2023;256: 156–163.

TODAY A WIDE PORTFOLIO OF PRESBYOPIA-CORRECTING IOLs is available, including bifocal, trifocal, and extended depth of focus (EDoF) or "monofocal plus" IOLs. The highest spectacle independence can be achieved with trifocal IOLs, which provide better optical quality than monofocal IOLs at near and intermediate distance.[1,2] They are superior to bifocal IOLs at intermediate distance[3,4] and provide better optical quality than EDoF IOLs at near distance.[2] However, trifocal IOLs are also associated with side effects such as reduced contrast sensitivity and positive dysphotopsia, namely, halo and glare.[5] For each case, an individual's tolerance to these side effects is difficult to predict. Young patients implanted with a trifocal IOL may, in the course of their lives, develop ocular pathologies in which the trifocal IOL proves disadvantageous.[6,7] The duet procedure, that is, the combined implantation of a monofocal or monofocal toric IOL in the capsular bag and of a trifocal supplementary IOL into the ciliary sulcus, offers the possibility of a reversible trifocality.[6-8]

The results with duet procedure are equivalent to those of a single capsular bag–fixated trifocal IOL, and the advantage is that there is an "exit strategy" in case of a loss of function or low tolerance to the side effects induced by the trifocal optic.[6-8] As with other trifocal IOLs, achieving the target refraction is crucial to obtain optimal results, and therefore in cases with corneal astigmatism, toric capsular bag–fixated IOLs are used. Surgical correction of a misaligned toric IOL would be more challenging in polypseudophakic eyes, as the IOL in the sulcus impedes access to the toric IOL in the capsular bag. Therefore, it is particularly important to question whether the rotational stability of the primary IOL in the capsular bag is affected by the presence of another IOL in the sulcus.

The purpose of this study was to determine the long-term rotational stability of the capsular bag–fixated toric intraocular lens in patients who underwent duet procedure for reversible trifocality.

PATIENTS AND METHODS

• **PATIENTS:** The retrospective interventional study was conducted in accordance with the tenets of the Declaration of Helsinki. Institutional review board (IRB) approval was obtained. The study is registered on the German Clinical Trials Register (Deutsches Register Klinischer Studien; reference numbers DRKS00007837 and DRKS00011251).

Accepted for publication August 8, 2023.
From the Department of Ophthalmology, University Clinic Heidelberg, Heidelberg, Germany.
Inquiries to Ramin Khoramnia, Department of Ophthalmology, University of Heidelberg, Heidelberg, Germany; e-mail: ramin.khoramnia@med.uni-heidelberg.de

0002-9394/$36.00
https://doi.org/10.1016/j.ajo.2023.08.006

FIGURE 1. Photograph of the Sulcoflex intraocular lens.

Informed consent for both the treatment and participation in the research was obtained.

Twenty patients who had either refractive lens exchange for presbyopia correction or cataract surgery were included in this study. Each patient had undergone phacoemulsification and implantation of a monofocal-toric IOL into the capsular bag and during the same surgery the subsequent implantation of a supplementary trifocal IOL into the ciliary sulcus to achieve reversible trifocality. Patients who underwent duet procedure at least 3 months ago were invited for follow-up visits. After obtaining informed consent, they were enrolled in the study.

• **INTRAOCULAR LENSES:** The capsular bag–fixated toric IOLs were either the RayOne toric (Rayner Intraocular Lenses Ltd), the XY1AT (Hoya Surgical Optics), or the Tecnis ZCT800 IOL (Johnson & Johnson Vision). The sulcus-fixated IOLs were Sulcoflex trifocal 703F (Rayner Intraocular Lenses Ltd) in all patients. Figure 1 shows a photograph of the trifocal Sulcoflex IOL. For patients who had received a toric capsular bag–fixated IOL in one eye and a monofocal capsular bag–fixated IOL in the fellow eye, only the eye implanted with the toric IOL was included in the study.

For IOL power calculation, we used each manufacturer's own toric calculator: the RayTrace Premium IOL calculator (Rayner Intraocular Lenses Ltd) for the RayOne toric IOLs, the Hoya toric calculator (Hoya Surgical Optics) for the Hoya Vivinex toric XY1AT2 IOLs, and the Tecnis toric calculator (Johnson & Johnson Vision) for the Tecnis ZCT800 IOLs. The IOL that would result in the lowest residual astigmatism was selected. All toric IOLs were implanted with image-guided navigation. All IOLs included in the analysis had loop haptics. The IOL specifications are shown in Table 1.

• **SURGICAL PROCEDURE:** The surgical procedure has been described in detail in our previous work.[6,7] In brief, after phacoemulsification, the monofocal-toric IOL is implanted into the capsular bag and correct axial alignment is achieved using image-guided navigation. After the viscoelastic device is completely removed, the supplementary trifocal IOL is implanted into the sulcus. Special attention is paid to avoiding a partial implantation, where the lens would be incompletely implanted in the capsular bag, as this could lead to tilting or decentration of the optic. After the viscoelastic device is removed, the correct alignment of the toric IOL is verified again and corrected if necessary. Then, the pupil is constricted with acetylcholine to minimize the risk of postoperative iris capture.

• **FOLLOW-UP EXAMINATION:** At the postoperative follow-up visit, the manifest refraction was obtained. Uncorrected and corrected distance visual acuity, uncorrected and distance corrected near visual acuity at 40 cm, as well as uncorrected and distance corrected intermediate visual acuity (DCIVA) at 80 cm were obtained with Early Treatment Diabetic Retinopathy Study (ETDRS) charts suitable for the respective distance.

• **ASSESSMENT OF ROTATIONAL STABILITY:** To assess axial alignment and determine rotational stability, we used the Pentacam AXL Wave device (Oculus GmbH). Retroillumination images as shown in Figure 2 were obtained for each eye implanted with a toric IOL. To achieve adequate visualization of the markings of the toric IOLs, mydriasis was induced by application of phenylephrine hydrochloride 5% eyedrops and tropicamide 5 mg/mL eyedrops at least 30 minutes prior to examination. Visibility of the markings was ensured via slitlamp examination prior to the Pentacam examination. Having obtained a retroillumination image with the Pentacam device, the overlay shown in Figure 2 was used to determine the position of the toric IOL's axis.

The position of the axis was compared to the calculated axis position obtained from IOL calculation documentation. The difference between the planned and measured axis position was calculated.

• **STATISTICAL ANALYSIS:** Statistical analysis was performed using Microsoft Excel version 16.32 for Mac and jamovi version 1.2.27 for Mac OS. For all quantitative parameters, we calculated the mean value and SD. The Student *t* test for paired samples was used to evaluate the refractive outcome and a significance level of $P < .05$ was adopted.

TABLE 1. IOL Specifications of the Different Toric IOLs and the Sulcoflex Trifocal IOL

	Manufacturer	IOL Design	IOL Material	IOL Diameter: Optic/Overall, mm
Sulcoflex trifocal 703 F	Rayner Intraocular Lenses Ltd	Convex anterior and concave posterior	Hydrophilic acrylic (26% water content)	6.5/14.0
RayOne toric	Rayner Intraocular Lenses Ltd	Biconvex (positive powers) Convex-concave (negative powers)	Hydrophilic acrylic (26% water content)	6.0/12.5
XY1AT	Hoya Surgical Optics	Biconvex	Hydrophobic acrylate	6.0/13.0
Tecnis ZCT800	Johnson & Johnson Vision	Biconvex	Hydrophobic acrylate	6.0/13.0

IOL = intraocular lens.



FIGURE 2. Assessment of rotational stability using the Pentacam device. Custom axes for toric intraocular lens alignment are displayed.

The ordinary least squares multiple regression analysis with 3 predictors of equal weight was performed with a significance level of $P < .05$. The resulting coefficients were subsequently assessed using the Omnibus F test for the significance of their deviation from zero.

G*power 3.1.9.6 was used for post hoc power analysis. It demonstrated that the sample size of the current study warranted a statistical power of 84% for the detection of a moderate ($R^2 = 0.4$) or higher effects, but falls short for smaller effects, that is, 18% for $R^2 = 0.062$. Although the power estimates for comparing the refractive outcomes suggest 99% power in detecting a 0.25D difference between the dependent samples, a minute difference observed between the mean target and achieved refraction resulted in a post hoc value of 49%.

RESULTS

Table 2 shows the patient characteristics.

• **VISUAL ACUITY AND REFRACTIVE OUTCOMES:** Mean target spherical equivalent (SE) was –0.14 ± 0.12, whereas the mean achieved SE was –0.04 ± 0.34 diopters (D). The difference between target and achieved SE was +0.03 ± 0.35, which was not statistically significant ($P = .45$). Table 3 shows the results for monocular and binocular visual acuity testing at far, intermediate, and near distances. The postoperative refractive cylinder was –0.14 ± 0.22 D on average. The refractive and visual acuity outcomes are illustrated in Figure 3.

TABLE 2. Patient Characteristics

Characteristic	Value
Age, y, mean ± SD	49 ±15
Sex, female/male, n	10/10
Implanted IOL, n	
RayOne toric	26
XY1AT	6
Tecnis ZCT800	2
IOL power, mean ± SD	19.54 ± 6.0
Torus, mean ± SD (range)	2.01 ± 1.8 (1.0-8.0)
Toric IOL implantation, binocular/monocular, n	14/6
Follow-up time, mo	
Mean ± SD	24 ± 15
Median (range)	27 (3-47)
Preoperative corneal cylinder, D	–1.94 ± 1.3
Preoperative refractive cylinder, D	–1.93 ± 2.0
Postoperative refractive cylinder, D	–0.14 ± 0.22

D = diopters, IOL = intraocular lens.

TABLE 3. Visual Acuity

Q	Monocular	Binocular
UDVA (4 m)	0.11 ± 0.12 (n=20)	0.05 ± 0.11 (n=14)
CDVA (4 m)	0.05 ± 0.08 (n=20)	0.02 ± 0.09 (n=14)
UNVA (40 cm)	0.04 ± 0.13 (n= 20)	0.01 ± 0.12 (n=14)
DCNVA (40 cm)	0.04 ± 0.11 (n=20)	0.02 ± 0.13 (n=14)
UIVA (80 cm)	–0.01 ± 0.13 (n=20)	–0.01 ± 0.11 (n=14)
DCIVA (80 cm)	–0.01 ± 0.11 (n=20)	–0.03 ± 0.11 (n= 14)

CDVA = corrected distance visual acuity, DCIVA = distance corrected intermediate visual acuity, DCNVA = distance corrected near visual acuity, UDVA = uncorrected distance visual acuity, UIVA = uncorrected intermediate visual acuity, UNVA = uncorrected near visual acuity.

Visual acuity testing results at the postoperative follow-up visit (mean values ± SDs) are in logMAR.

• **ROTATIONAL STABILITY:** The mean deviation from the calculated cylinder axis was 3.8± 3.5°, with a median of 2.8° and a maximum deviation of 15.0°. Figure 4 shows a box plot of the axial misalignment split by IOL model. Ninety-four percent of all eyes showed a rotation of less than 10°.

Two eyes showed a misalignment of more than 10°: both implanted with a RayOne Toric IOL (Figure 4). Uncorrected distance visual acuity was good (0.10 logMAR and 0.04 logMAR) in both eyes. In one of these cases, the manifest refraction was plano; therefore, no further intervention was planned. For the other case, the webpage www.astigmatismfix.com was used to evaluate possible benefit from realignment of the IOL. The calculation is made using the manifest refraction and IOL model implanted as well as the current axial misalignment. The calculation suggested that in this case the astigmatism could have been only minimally reduced (by 0.37 D) by a surgical reintervention. After a risk-benefit assessment, it was decided not to intervene.

We did not find a statistically significant correlation between the axial misalignment and anterior chamber depth, axial length, or white-to-white values ($P > .05$). The 3 factors combined explained 6.2% of the variance in axial misalignment. $R^2 = .062$, $F(3, 30) = 0.64$, $P = .59$ (Omnibus F test).

DISCUSSION

In this clinical study, we investigated the axial alignment and long-term rotational stability of toric capsular bag–fixated IOLs in polypseudophakic eyes after duet procedure. We found a mean axial misalignment of 3.8± 3.5° in our patient collective. In polypseudophakic eyes, the repositioning of a toric IOL to achieve perfect axial alignment would be more challenging than in an eye with only 1 capsular bag–fixated IOL, as the additive IOL makes access to the toric IOL more difficult. However, an optimal refractive result is especially a prerequisite with trifocal supplementary IOLs, to achieve the desired spectacle independence: thus, one needs the best possible correction of cylinder.

The design of the Sulcoflex with a concave posterior surface and 10° of posterior angulation of the haptics ensures a distance between the iris tissue and the capsular bag–fixated IOL.[9,10] The Sulcoflex IOL should, therefore, not interact with the capsular bag–fixated IOL. However, after conducting a literature review on January 6, 2023, utilizing PubMed and Google Scholar using the key words *duet procedure*, *supplementary IOL*, *additive IOL*, and *polypseudophakia*, we did not find any prior reports assessing a possible influence on rotational stability of toric IOLs in the capsular bag. An aim of this study was to assess whether the placement of an IOL in the sulcus in close proximity to the toric IOL could compromise rotational stability of the capsular bag–fixated toric IOL.

There are different options to assess axial alignment of toric IOLs. In clinical routine, slitlamp examination is commonly used to evaluate the position of toric IOLs, aligning the slit beam with the IOL axis. Alternative methods have been proposed: Carey and associates,[11] for example, compared slitlamp observation to the internal map of a corneal analyzer (Nidek OPD-Scan refractive power/corneal analyzer system). They found good correlation between both methods. Teichman and associates[12]

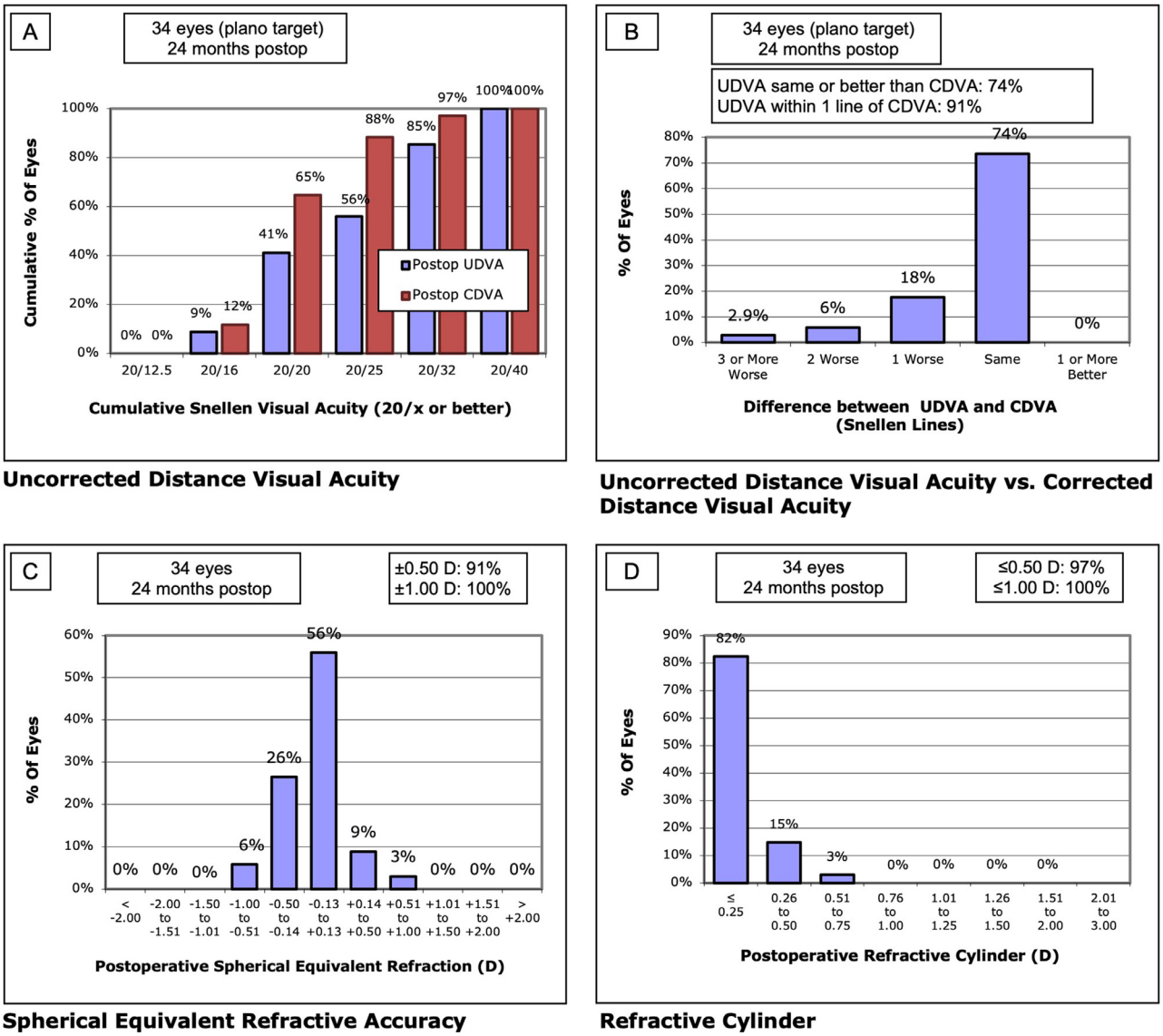

FIGURE 3. A. Cumulative percentage of eyes with postoperative uncorrected distance visual acuity (UDVA) and corrected distance visual acuity (CDVA) levels indicated. B. Difference between postoperative UDVA and CDVA. C. Postoperative spherical equivalent refraction. (D) Postoperative refractive cylinder.

published a method using a smartphone to capture retroillumination images and ImageJ software for measurement of axial alignment. Watanabe and associates[13] used anterior segment optical coherence tomography to evaluate axial alignment.

We used the Pentacam AXL wave device to assess the position of the toric IOL. As of this writing, these different methods have not been sufficiently compared to establish a gold standard. Our method has the advantage, which theoretically could increase reproducibility, in that we make the measurement from an image rather than using in vivo slitlamp microscopy. However, most methods, including the one we applied, require subjective judgment from the examiner.

The mean axial misalignment we found is comparable to what was reported for different monofocal-toric IOLs. For the Acrysof IQ toric SN6AT (Alcon), different studies found a mean misalignment ranging from 2.66° ± 1.99° to 4.5° ± 4.9°.[14,15] For the XY-1 IOL, a mean misalignment of 5.43° ± 4.67 was reported.[16] The platform of the RayOne toric IOL was found to show a mean rotation of 1.83° ± 1.44° in a clinical study examining the Rayner 600S.[17]

Mendicute and associates[18] studied the Acrysof IQ toric SN6AT and found that 96.7% of eyes showed a rotation of less than 10°. Osawa and associates[16] found that 89.1% of eyes implanted with the XY-1 IOL showed an axial misalignment of less than 10°. In the study by Bhogal-Bhamra and associates[17] assessing the RayOne toric platform, no

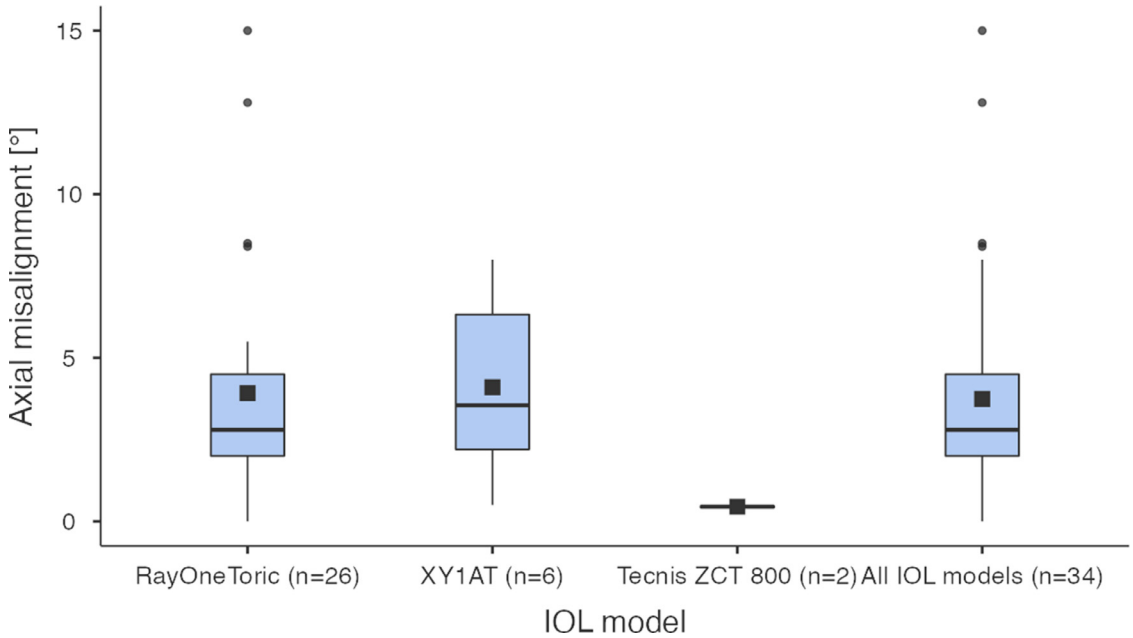

FIGURE 4. Axial misalignment by intraocular lens (IOL) model. The squares represent the mean values for the different IOL models. The box plots with median, upper, and lower quartile as well as outliers are shown.

IOL rotated by more than 5°. In our patient collective comprising polypseudophakic eyes, the proportion of eyes achieving the 10° target was comparable to the values reported in the literature for only one capsular bag–fixated IOL with 94%.

The results with the polypseudophakic approach using a toric IOL in the capsular bag and trifocal Sulcoflex IOL in the ciliary sulcus compare to those reported for trifocal toric IOLs. For the FineVision Pod FT trifocal toric IOL (PhysIOL SA), a mean axial misalignment of 2.55° ± 2.62° has been reported. Uncorrected distance visual acuity with this IOL was 0.11 ± 0.10 logMAR.[19] For the AT Lisa tri toric 939 MP (Carl Zeiss Meditec) an axial misalignment of 5.80 ± 8.47 and uncorrected distance visual acuity of 0.03 ± 0.11 logMAR, uncorrected near visual acuity of 0.16 ±0.09 and uncorrected intermediate visual acuity of 0.09 ± 0.11 were reported.[20] Rementería-Capelo and associates[21] examined the toric version of the PanOptix IOL (Alcon) and found uncorrected distance visual acuity of 0.07 ±0.10, uncorrected near visual acuity of 0.07 ± 0.12, and uncorrected intermediate visual acuity of 0.23 ± 0.20 logMAR. Axial alignment was not reported.

In an earlier publication, we evaluated the functional outcomes of cataract and refractive lens exchange patients who underwent duet procedure with the Sulcoflex IOL for reversible trifocality. The visual acuity results we found in our patient cohort implanted with toric IOLs differs less than one line from the results in our earlier work.[6] The follow-up time of both studies differed considerably, with a mean follow-up of 3.58 ± 1.87 months in the previously published work[6] vs 24 ±15 months in the current study. This shows that not only early postoperative results are comparable to outcomes reported for capsular bag–fixated trifocal diffractive IOLs,[6] but long-term follow-up yielded similar results.

Inoue and associates[22] examined axial alignment at different time points after IOL implantation and found that the greatest misalignment occurred from IOL rotation within 1 hour of surgery. This was significantly higher than the misalignments noted at other postoperative intervals (1 day, 1 month, 3 months, and 1 year after surgery). Thus, after the early postoperative period, the risk for IOL rotation appears to be comparatively low. These findings are in good agreement with our results.

The clinical data are supported by in vitro studies that compared mono- with poly-pseudophakia. The presence of 2 instead of 1 IOL does not decrease optical quality. Interface reflection, material absorption, and light scatter from the additional IOL only leads to minimal light loss of 1.3% compared to a single capsular bag–fixated IOL.[23,24] A very good centration with a maximum decentration of 0.6 mm for the additive Sulcoflex IOL in the ciliary sulcus has been shown in a clinical study.[25] The tolerance to decentration of up to 1 mm and tilt of up to 10° for the aspheric Sulcoflex was assessed using ray tracing simulation in a laboratory study. Decentration showed only minimal effect on the optical quality of Sulcoflex IOLs, ranging from 1 to 10 D spherical power compared to a capsular bag IOL with an IOL power of 20 D.

Tilt also showed greater impact on IOLs with higher spherical power.[26] Although the optical quality is more affected by decentration in trifocal IOLs than in monofocal

IOLs,[27] the moderate amounts of decentration reported in clinical studies can be expected to have only a limited effect on imaging quality.[6,25]

The advantage of duet procedure for reversible trifocality is that it can be more easily reversed with removal of the sulcus lens than explanting a trifocal IOL from the capsular bag. This may be beneficial in patients who develop an ocular pathology in the course of their lives that leads to a loss of function, that is, macular degeneration, glaucoma, or retinal detachment. In these cases, the trifocal optic may be detrimental and, compared with patients with a single trifocal IOL, the additive sulcus-fixated IOL may then be removed from the eye with a lower risk of posterior capsular rupture and vitreous loss.[6-8]

The same applies to patients who cannot tolerate side effects such as loss of contrast sensitivity or perception of dysphotopsia induced by trifocal optics. In myopic patients, the target refraction of the monofocal (-toric) IOL in the capsular bag also can be selected in the myopic range. This would lead to a myopic refraction in case of the removal of the supplementary IOL, which can be the preferred option in (high) myopes.[6,7,28] This approach was chosen for one patient included in this analysis with a preoperative spherical equivalent refraction of –4.75 and –3.63 D for the right and left eye, respectively.

A limitation of our study is that we did not compare the axial alignment to early postoperative or intraoperative measurements. We used the data from preoperative planning because intraoperative and early postoperative values were not available for all patients and, if available, measurement was performed using different methods, that is, slitlamp examination instead of Scheimpflug imaging that we used at the follow-up visit in this study. Another weakness may be that we used different toric IOL models rather than 1 model. However, our aim was not to compare different IOLs, and we did not draw conclusions on differences in rotational stability between the IOL models.

In duet procedure, the toric IOL that is implanted in the capsular bag can be aligned using image-guided navigation. Having obtained the desired alignment of the IOL axis, however, further surgical manipulation including the use of ophthalmic viscoelastic device is required to implant the second IOL into the ciliary sulcus. Therefore, the correct toric IOL's alignment is verified again after implantation of the supplementary trifocal IOL and corrected if necessary. Axial misalignment values at our long-term follow-up visits were comparable to those reported in the literature for approaches using only 1 capsular bag–fixated monofocal-toric or trifocal-toric IOL. Thus, intraoperative and early postoperative alignment of the IOL also can be considered to be comparable in polypseudophakia.

In conclusion, in duet procedure patients, we found excellent alignment and long-term rotational stability of the capsular bag–fixated toric IOL. Refractive astigmatism was effectively reduced by implantation of a toric capsular bag–fixated IOL. This is of particular importance to achieve spectacle independence with a trifocal additive IOL. Duet procedures provided good long-term functional results at different distances.

Acknowledgments: Donald J. Munro contributed to reviewing and proofreading of the manuscript.
Funding/Support: Isabella D. Baur is funded by the Rahel Goitein-Straus-Programme of Heidelberg University, Faculty of Medicine. Financial Disclosures: R. Khoramnia reports research grants and lecture fees from Alcon, Hoya, PhysIOL, Rayner, 1stQ, and Johnson & Johnson; lecture fees from Kowa, Ophtec, Teleon, Santen, Acufocus, and Bausch&Lomb; and travel grants from Alcon, Teleon, Johnson & Johnson, Rayner, and 1stQ. Gerd U. Auffarth reports research grants, travel grants, and lecture fees from Alcon, Hoya, Kowa, SIFI; research grants and lecture fees from Johnson & Johnson and Santen; and research grants from Zeiss, PhysIOL, and Acufocus. Isabella D. Baur reports travel grants from Santen. The remaining authors have nothing to disclose. All authors attest that they meet the current ICMJE criteria for authorship.

REFERENCES

1. Modi S, Lehmann R, Maxwell A, et al. Visual and patient-reported outcomes of a diffractive trifocal intraocular lens compared with those of a monofocal intraocular lens. *Ophthalmology*. 2021;128(2):197–207.
2. Monaco G, Gari M, Di Censo F, Poscia A, Ruggi G, Scialdone A. Visual performance after bilateral implantation of 2 new presbyopia-correcting intraocular lenses: trifocal versus extended range of vision. *J Cataract Refract Surg*. 2017;43(6):737–747.
3. Son HS, Tandogan T, Liebing S, et al. In vitro optical quality measurements of three intraocular lens models having identical platform. *BMC Ophthalmol*. 2017;17(1):108.
4. Gatinel D, Houbrechts Y. Comparison of bifocal and trifocal diffractive and refractive intraocular lenses using an optical bench. *J Cataract Refract Surg*. 2013;39(7):1093–1099.
5. Breyer DR, Kaymak H, Ax T, Kretz FT, Auffarth GU, Hagen PR. Multifocal intraocular lenses and extended depth of focus intraocular lenses. *Asia Pac J Ophthalmol (Phila)*. 2017;6(4):339–349.
6. Baur ID, Auffarth GU, Łabuz G, Khoramnia R. Clinical outcomes in patients after duet procedure for reversible trifocality using a supplementary trifocal intraocular lens. *Am J Ophthalmol*. 2022;241:217–226.
7. Khoramnia R, Yildirim TM, Son H-S, Łabuz G, Mayer CS, Auffarth GU. Duet procedure to achieve reversible trifocality. *Der Ophthalmologe*. 2020;117:999–1004.
8. Baur ID, Auffarth GU, Yildirim TM, Mayer CS, Khoramnia R. Reversibility of the duet procedure: bilateral exchange of a supplementary trifocal sulcus-fixated intraocular lens for correction of a postoperative refractive error. *Am J Ophthalmol Case Rep*. 2020;20:100957.
9. Kahraman G, Amon M. New supplementary intraocular

lens for refractive enhancement in pseudophakic patients. *J Cataract Refract Surg*. 2010;36(7):1090–1094.
10. Baur ID, Labuz G, Yildirim TM, Auffarth GU, Khoramnia R. Reversible Multifokalität durch Polypseudophakie [Reversible multifocality achieved through polypseudophakia]. Article in English, German. *Klin Monbl Augenheilkd*. 2023;240(8):981–988.
11. Carey PJ, Leccisotti A, McGilligan VE, Goodall EA, Moore CT. Assessment of toric intraocular lens alignment by a refractive power/corneal analyzer system and slitlamp observation. *J Cataract Refract Surg*. 2010;36(2):222–229.
12. Teichman JC, Baig K, Ahmed IIK. Simple technique to measure toric intraocular lens alignment and stability using a smartphone. *J Cataract Refract Surg*. 2014;40(12):1949–1952.
13. Watanabe K, Negishi K, Torii H, Saiki M, Dogru M, Tsubota K. Simple and accurate alignment of toric intraocular lenses and evaluation of their rotation errors using anterior segment optical coherence tomography. *Jpn J Ophthalmol*. 2012;56(1):31–37.
14. Miyake T, Kamiya K, Amano R, Iida Y, Tsunehiro S, Shimizu K. Long-term clinical outcomes of toric intraocular lens implantation in cataract cases with preexisting astigmatism. *J Cataract Refract Surg*. 2014;40(10):1654–1660.
15. Koshy JJ, Nishi Y, Hirnschall N, et al. Rotational stability of a single-piece toric acrylic intraocular lens. *J Cataract Refract Surg*. 2010;36(10):1665–1670.
16. Osawa R, Oshika T, Sano M, Yuguchi T, Kaiya T. Rotational stability of modified toric intraocular lens. *Plos One*. 2021;16(3):e0247844.
17. Bhogal-Bhamra GK, Sheppard AL, Kolli S, Wolffsohn JS. Rotational stability and centration of a new toric lens design platform using objective image analysis over 6 months. *J Refract Surg*. 2019;35(1):48–53.
18. Mendicute J, Irigoyen C, Aramberri J, Ondarra A. Montés-Micó R. Foldable toric intraocular lens for astigmatism correction in cataract patients. *J Cataract Refract Surg*. 2008;34(4):601–607.
19. Vandekerckhove K. Rotational stability of monofocal and trifocal intraocular toric lenses with identical design and material but different surface treatment. *J Refract Surg*. 2018;34(2):84–91.
20. Mojzis P, Majerova K, Plaza-Puche AB, Hrckova L, Alio JL. Visual outcomes of a new toric trifocal diffractive intraocular lens. *J Cataract Refract Surg*. 2015;41(12):2695–2706.
21. Rementería-Capelo LA, Contreras I, García-Pérez JL, Blázquez V, Ruiz-Alcocer J. Visual quality and patient satisfaction with a trifocal intraocular lens and its new toric version. *J Cataract Refract Surg*. 2019;45(11):1584–1590.
22. Inoue Y, Takehara H, Oshika T. Axis misalignment of toric intraocular lens: placement error and postoperative rotation. *Ophthalmology*. 2017;124(9):1424–1425. doi:10.1016/j.ophtha.2017.05.025.
23. Łabuz G, Auffarth GU, Knorz MC, Son HS, Yildirim TM, Khoramnia R. Trifocality achieved through polypseudophakia: optical quality and light loss compared with a single trifocal intraocular lens. *J Refract Surg*. 2020;36(9):570–577.
24. Khoramnia R, Baur ID, Yan W, Łabuz G, Auffarth GU. Comparison of a presbyopia-correcting supplementary intraocular lens combination and a capsular-bag lens: an in vitro study. *Diagnostics*. 2023;13(8):1482.
25. Prager F, Amon M, Wiesinger J, Wetzel B, Kahraman G. Capsular bag–fixated and ciliary sulcus-fixated intraocular lens centration after supplementary intraocular lens implantation in the same eye. *J Cataract Refract Surg*. 2017;43(5):643–647.
26. Łabuz G, Auffarth GU, Yan W, Yildirim TM, Khoramnia R. *Simulations of Decentration and Tilt of a Supplementary Sulcus–Fixated Intraocular Lens in a Polypseudophakic Combination Using Ray-Tracing Software* Multidisciplinary Digital Publishing Institute; 2021:309.
27. Tandogan T, Son HS, Choi CY, Knorz MC, Auffarth GU, Khoramnia R. Laboratory evaluation of the influence of decentration and pupil size on the optical performance of a monofocal, bifocal, and trifocal intraocular lens. *J Refract Surg*. 2017;33(12):808–812.
28. Yildirim TM, Auffarth GU, Son HS, Mayer CS, Tandogan T, Khoramnia R. Duettverfahren bei hoher Myopie zum Erreichen einer reversiblen Multifokalität. [Duet procedure in high myopia to achieve reversible multifocality]. Article in English, German. *Klin Monbl Augenheilkd*. 2020;237(8):958–960. doi:10.1055/a-0916-8780.