

# The brains behind the BAD

## Simplifying pre-operative keratoconus screening

Michael W. Belin, MD,<sup>a</sup>  
FACS, Renato Ambrósio  
Jr.,<sup>b</sup> MD, PhD & Andreas  
Steinmueller, MSc<sup>c</sup>

<sup>a</sup> Albany, New York (USA), <sup>b</sup> Rio de  
Janeiro, Brazil, <sup>c</sup> Wetzlar, Germany

The early detection of ectatic change is of paramount importance to the refractive surgeon. Anterior curvature and ultrasonic pachymetry, alone, does not provide enough information to detect early corneal disease. The combination of anterior and posterior elevation and complete pachymetric data gives the clinician a more complete view of the structure of the cornea and allows for more effective screening. The OCULUS Pentacam's Scheimpflug Cross-sectional imaging (OCULUS Optikgerate GmbH, Wetzlar, Germany) provides for a three-dimensional reconstruction of the anterior segment, making possible the assessment of the anterior and posterior corneal surfaces and the creation of a complete pachymetric map. The Belin / Ambrósio Enhanced Ectasia Display (BAD display) was designed to

utilise the data supplied by the Pentacam's rotating Scheimpflug camera and provide a comprehensive keratoconus screening display. The display combines the anterior and posterior elevation and pachymetric data into one all-inclusive display giving the clinician a more complete overview of the corneal shape and allowing for quick and effective screening of refractive surgery patients.

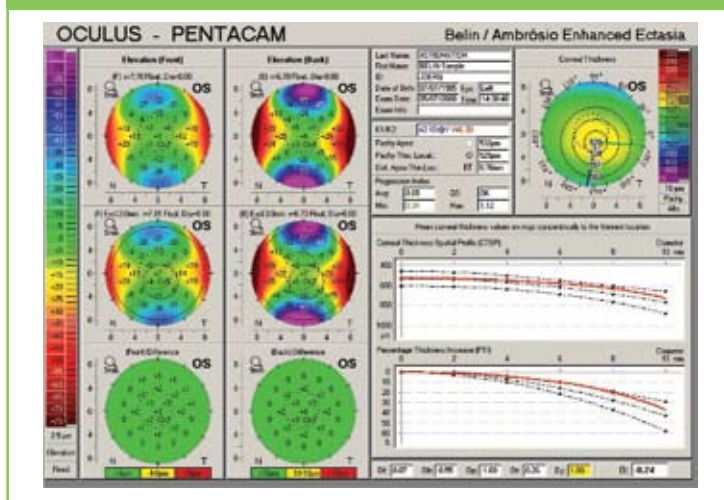
The current display (Belin / Ambrósio Enhanced Ectasia Display – software release # 1-16b96) shows both anterior and posterior elevation data relative to a standard best-fit-sphere (BFS) calculated at a fixed optical zone of 8.0 mm. Fitting a best-fit-sphere to the central 8.0 mm zone appears best for clinical interpretation and allows for the generation of standardised normal values. The display also shows anterior and posterior elevation values relative to the 'enhanced reference surface' computed by determining the BFS from the central 8.0 mm zone after excluding all the data from a 3.5 mm optical zone centred on the thinnest point of the cornea. Not often appreciated is that the BFS will be influenced by any abnormal portion of the cornea. In the case of keratoconus or ectasia, the cone will have the effect of steepening the BFS. This steepened BFS will actually minimise the elevation difference between the apex of the cone and the BFS. By eliminating the conical portion of the cornea from the BFS computation, the 'enhanced reference surface' serves to further accentuate ectatic or conical protrusion, while having little if any effect on normal corneas. The BAD display then computes the change in elevation values going from the standard BFS and the 'enhanced BFS.' This change (elevation change between the standard BFS and 'enhanced BFS') has been shown to be a key differentiator between normal and ectatic corneas.

### *In short...*

Drs Belin and Ambrósio's Enhanced Ectasia module is a keratoconus index, based on pachymetry and elevation. Here they explain how they hope the new version will simplify the interpretation of maps and provide greater specificity and sensitivity for detecting early ectatic disease.

The BAD display also contains a comprehensive pachymetric evaluation. Both pachymetric values at the apex and thinnest points are displayed and the displacement of the thinnest point from the corneal apex is calculated along with the direction of the displacement. The distance between the thinnest point and the geometric central point is significantly higher in keratoconus. Graphical representations of the progressive thickening of the cornea from the thinnest point to the periphery are depicted in the 'Corneal Thickness Spatial Profile' (CTSP). The 'Percentage Thickness Increase' (PTI) refers to the percentage of increase from the thinnest point to the periphery. The data from both graphs are calculated from the pachymetric values at 22 concentric rings centred on the thinnest point. Corneas with ectatic disease (e.g. keratoconus, post LASIK ectasia) show a more rapid progression of thickening from the thinnest point to the periphery. This increase follows a normal pattern and is a strong differentiator between normal and keratoconic corneas. A more intuitive way of saying the same is that ectatic corneas thin more rapidly than normal eyes going from the periphery to the thinnest part of the cornea. The CTSP and PTI display provides the average progression derived from a normal population (centre line) and  $\pm 2$  SD (95% confidence interval) against the patient's own data shown in red. This allows the clinician to differentiate a normal thin cornea from one with early ectatic disease. The 'progression index' is calculated as the progression value at the different rings, referenced to the mean curve. The best cut off point is 1.35, with sensitivity over 92% and specificity of 85%. These parameters allow for the differentiation of a normal thin cornea versus ectasia, as well as from a normal thick cornea

**Figure 1:** This is an example of an eye with high astigmatism and a displaced apex. The Belin/Ambrósio display shows a classical astigmatic pattern on the anterior and posterior elevation maps and the corneal thickness and pachymetric progression fall within the normal range. The thinnest point, however, is slightly inferior giving a "Yellow" warning for the "Dy" parameter. The final overall "D" reading shows that this map falls within an acceptable range.



versus one with early oedema.

The combination of the pachymetric graphs and indices and elevation maps which utilise an 'enhanced reference sphere' make possible an increased sensitivity and specificity in the screening of patients for ectatic disease. Each of these values (change in anterior elevation, change in posterior elevation, corneal thickness at the thinnest point, thinnest point displacement, and pachymetric progression) can be evaluated against a previously determined set of normal values to assist the physician in determining 'normal,' 'suspicious' and 'abnormal' corneas. The physician would evaluate each individual portion of the BAD display in conjunction with other data (e.g. ablation depth, age, family history, etc.) to make a clinical decision on the appropriateness of the patient's surgical candidacy.

The newest software release (Belin / Ambrósio Enhanced Ectasia Display II – software # 1-

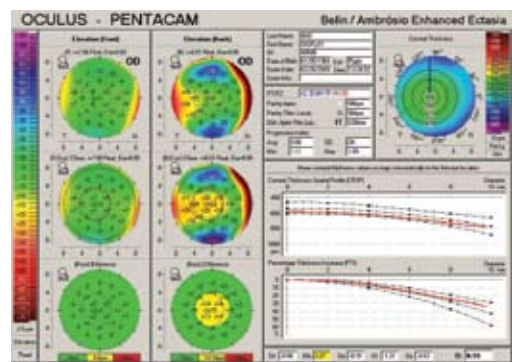
17b31) takes this evaluation one step further by looking at the five previous mentioned parameters (change in anterior elevation, change in posterior elevation, corneal thickness at the thinnest point, thinnest point displacement, and pachymetric progression) and performing a regression analysis against a standard data base of normal and keratoconic corneas. It reports five new terms (*D* values for standard deviation from the mean) representing the front surface (*Df*), back surface (*Db*), pachymetric progression (*Dp*), thinnest point (*Dt*), and thinnest point displacement (*Dy*). A sixth term (**D**) is the final overall map reading taking each of the five parameters into account. Each individual parameter *D* and the final **D** number have been normalised to their mean value and are reported as standard deviations from the mean. The individual parameters are also colour coded based on their variation from the norm. The parameter is indicated in YELLOW (suspicious)



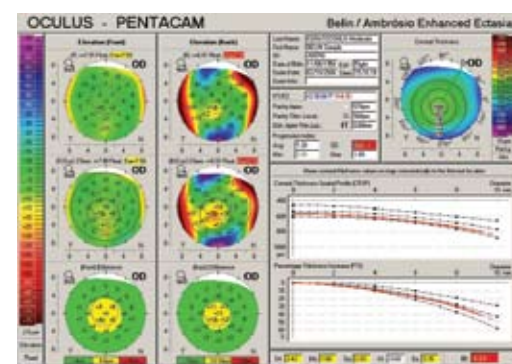
when it is  $\geq 1.6$  SD from the mean and turns RED (abnormal) at  $\geq 2.6$  SD from the mean. Values below 1.6 SD are reported in WHITE and are viewed as

within the normal range. The major advance is that while an individual parameter(s) may fall outside the norm the final overall comprehensive reading may still be viewed as normal (Figures 1 & 2). Conversely, multiple YELLOW or suspicious parameters may be significant enough for the final reading **D** to be RED or abnormal (Figure 3).

**Figure 2:** This eye shows a large yellow region on the posterior elevation difference map and consequently a "Yellow" "Db" reading that is 2.27 SD from the norm. All the other parameters, however, are well within the normal range yielding a final "D" that is within normal limits.



**Figure 3:** This eye depicts the usefulness of the regression analysis. While no individual parameter is in the "Red" zone, the combination of a large number of "Yellow" or borderline values (anterior surface "Df", posterior surface "Db", Pachymetric progression "Dp" and Thinnest point displacement "Dy") when present together may lead to an abnormal ("Red") display.



### Conclusion

The Belin / Ambrósio Enhanced Ectasia Display is the first comprehensive refractive surgical screening tool to be fully elevation based and to incorporate data from the posterior corneal surface and corneal thickness map. The newest release (version II) takes the analysis one step further by normalizing each parameter (allowing for an easier interpretation of relative risk) and provides a final overview reading ("D" value) of the entire map. It is hoped that this additional information will simplify the interpretation of the maps and provide greater specificity and sensitivity for detecting early ectatic disease.



### Authors

**Michael W. Belin, MD, FACS** is Professor & Director of Cornea & Refractive Surgery at Albany Medical College Lions Eye Institute, Albany, New York in the USA. He is also a consultant to OCULUS and can be reached by Email: MWBelin@aol.com

**Renato Ambrósio Jr., MD, PhD** is Associate Professor of Ophthalmology Pontific Catholic University, Scientific Coordinator of the Rio de Janeiro Corneal

Tomography & Biomechanics Study Group and Director of Cornea and Refractive Surgery of Instituto de Olhos Renato Ambrósio, Visare Personal Laser and Refracta. He is also a consultant to OCULUS and can be reached by Email: renatoambrosiojr@terra.com.br

**Andreas Steinmueller, MSc** is employed by OCULUS Optikgerate GmbH Wetzlar, Germany. He can be reached at Email: a.steinmueller@oculus.de

Article Reprinted from ©September 2009 issue of

**Ophthalmology Times**  
AN ADVANSTAR PUBLICATION EUROPE



# Let's get ready for the Anterior Segment Show!

Oculus proudly presents: The Pentacam for all your needs

## Pentacam BASIC

### The Individual

Ambitious anterior segment diagnostics personalized to your individual needs

## Pentacam CLASSIC

### The Versatile

Wide-ranging, high precision anterior segment diagnostics for your daily work

## Pentacam HR

### The Professional

Comprehensive premium diagnostics in high resolution for your most sophisticated claims