

# *The Pentacam: Precision, Confidence, Results, and Accurate “Ks!”*

Produced under an unrestricted educational grant from Oculus, Inc.

This monograph is based on an informational symposium presented at the 2006 AAO meeting in Las Vegas. The symposium informed attendees about the diagnostic capabilities of the Pentacam Comprehensive Eye Scanner as well as how best to integrate this pioneering instrument into clinical practice.

**MICHAEL W. BELIN, MD, FACS, MODERATOR**

**JACK T. HOLLADAY, MD, MSEE, FACS**

**MARC A. MICHELSON, MD**

**J. TREVOR WOODHAMS, MD**

**IQBAL “IKE” K. AHMED, MD, FRCS**

## **BY MICHAEL W. BELIN, MD, FACS** **READING THE PENTACAM'S** **MAPS**

**Pattern recognition for screening patients for refractive surgery.**

Many surgeons who use the Pentacam Comprehensive Eye Scanner (Oculus, Inc., Lynnwood, WA) for the first time worry about misinterpreting the images and mistakenly including or excluding refractive surgery candidates. The key to successfully screening patients with the Pentacam is to create a standardized template that always displays the same maps in the same order using consistent colors and scales. Once you become familiar with the system, you should be able to recognize patterns that tell you if the patient's eyes are normal, usually in a matter of minutes, if not seconds.

### **MY ROUTINE USE**

I use the Pentacam's four-picture composite report (Figure 1), which includes anterior elevation, posterior

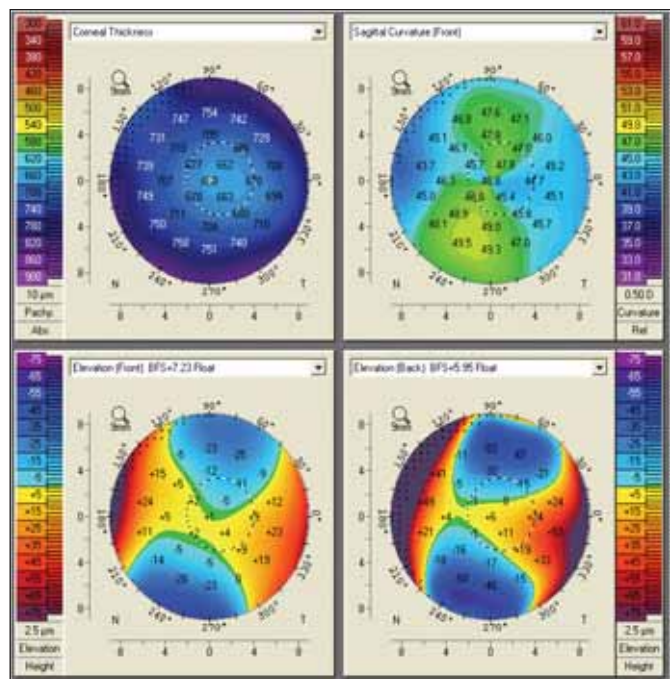


Figure 1. The Pentacam composite shows four maps at once.

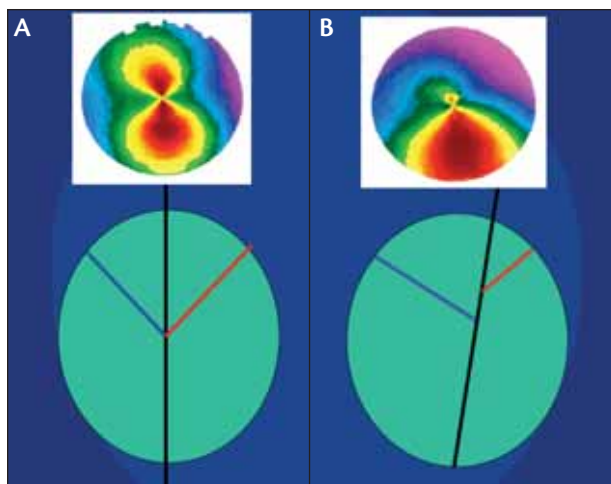


Figure 2. The same eye imaged through two different references axes seems to show astigmatism (A) or keratoconus (B).

elevation, pachymetry or corneal thickness, and sagittal curvature maps. I use the first three maps the most. I use best-fit sphere and float for the elevation map setting. My screening display for refractive surgery uses the  $\pm 75\text{-}\mu\text{m}$  elevation scale for all my refractive patients (I use a  $\pm 150\text{-}\mu\text{m}$  scale in my medical practice since I am evaluating pathology, not screening for normal patients). I use the color scale called *intuitive*, which I developed for Oculus, Inc., when I screen elevation and pachymetry maps. I limit my display so that it shows only the central 9-mm zone of the eye. Although the machine defaults to 12mm (it covers all the way out to the limbus), I find the central 9mm easier to look at clinically and for surgical screening. The placement of the different maps in the composite display does not matter, as long as it is consistent.

### **CURVATURE MAPS NOT THE MOST INFORMATIVE**

I have been speaking about the limitations of curvature maps for more than 10 years, and I think surgeons tend to place too much emphasis on sagittal curvature. The curvature map, to a degree, reflects the anterior elevation, but it has many limitations that do not exist on the elevation map. Curvature is a reference-based measurement that changes with the angle of evaluation. These maps assume that the apex line of sight and the reference axis are the same, and they are not. Also, we incorrectly assume that people always look through the center of their corneas, and that the center of the cornea, the apex, and the pupillary center share the same location. If these points differ from one another, they can distort the sagittal curvature map and provide inaccurate clinical information.

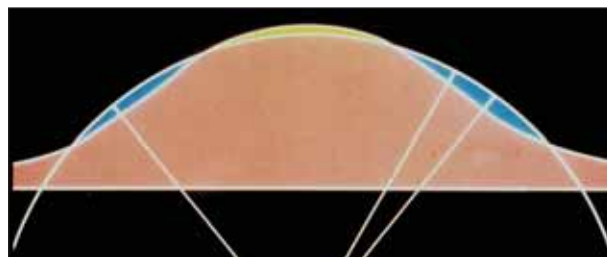


Figure 3. Elevation points above the best-fit sphere are positive; numbers below the best-fit sphere are negative.

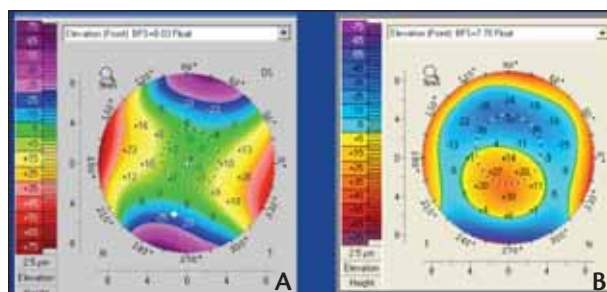


Figure 4. Astigmatism has a flat axis that falls above the best-fit sphere and a steep axis that falls below it (A and B).

In Figure 2, the curvature map on the left (A) seems to show a fairly normal astigmatic cornea, and the one of the right (B) seems to show a very suspicious-looking keratoconic eye. In actuality, these maps are of the same eye with different reference axes for curvature. Surgeons also tend to believe that the properties of the posterior corneal surface are less important than those of the anterior corneal surface. These two surfaces are equally important; in fact, the posterior corneal surface is probably more sensitive to pathology and more likely to show subtle changes earlier than the anterior surface. If you exclusively screen refractive patients based on their anterior corneal surfaces, you may miss important and potentially critical information.

### **POSTERIOR ELEVATION MUST BE ACCURATE**

Accurate posterior elevation data are a requisite for accurate pachymetry, because pachymetry is simply the difference between the anterior and posterior surfaces. Because what we look at is not the real elevation data, we use an approach that allows us to pick up subtle changes. We compare the elevation to a shape, the most common being a best-fit sphere. We do not look at the actual elevation, but rather a representation to make it obvious that a shape has undergone change (Figure 3).

### **UNDERSTANDING ECTATIC MAPS**

The Pentacam slide that probably is the most important

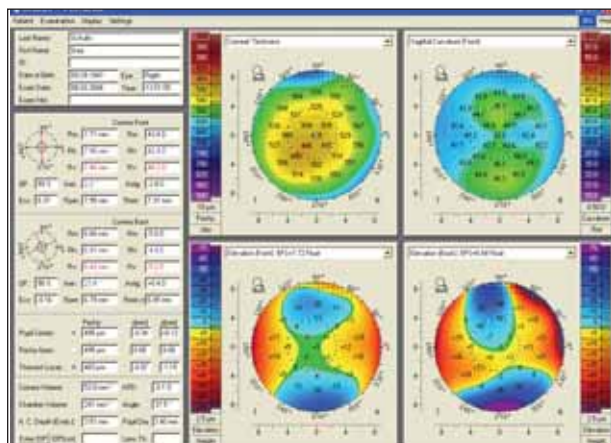


Figure 5. Ectatic eyes often have islands of elevation above the best-fit sphere.

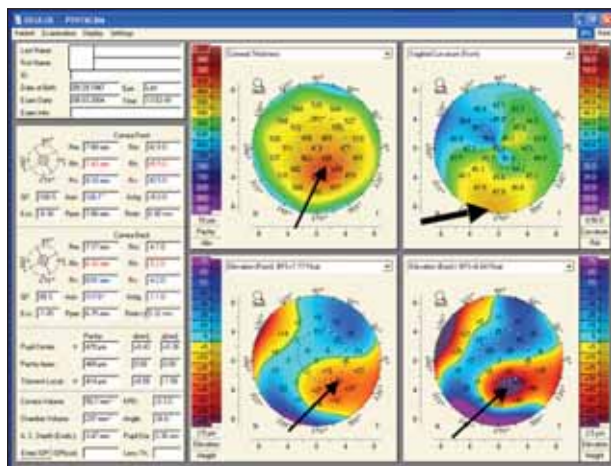


Figure 6. Cone is often mistaken for pellucid marginal degeneration.

and yet causes the most confusion is the comparison between elevation related to astigmatism and that which is abnormal secondary to an ectatic condition. Figure 4 shows an astigmatic map (A) and an ectatic map (B). How much elevation or depression exists in astigmatism does not matter, because by definition, astigmatism will have a flat axis that will fall above the best-fit sphere and a steep axis below this sphere. An astigmatic pattern may have +30.00 $\mu$ m in the flat axis and -30.00 $\mu$ m in the steep axis.

The pachymetric map represents the thickness distribution throughout the cornea. It shows corneas that are not only thin, but with their thinnest portion significantly displaced. At times, the pachymetric distribution may be the most sensitive or earliest indicator of an ectatic disorder and may be abnormal in spite of a normal anterior corneal surface.

Figure 5 shows another example of a normal anterior surface but an ectatic area. Look for islands of elevation above the best-fit sphere. In this eye, the curvature and anterior elevation look normal, but the pachymetric distribution is displaced inferiorly. The pachymetric distribution reflects that there is a very dramatic island on the posterior elevation. This is a map that should be very suspicious for early ectatic degeneration.

In Figure 6, sagittal curvature has also been used to define the morphology of the cone in keratoconus. The limitation of curvature makes this parameter an unreliable indicator for locating the cone. Many refractive surgeons are reporting a high incidence of pellucid marginal degeneration (PMD) based on topographic curvature diagnosis. The vast majority of these cases are not true PMD, but reflect the limitation of trying to define "shape" while looking at a sagittal curvature map. These patients typically represent normal keratoconus with inferiorly displaced cones that get incorrectly located. In Figure 6, you can see that the anterior elevation, the posterior elevation, and the pachymetric distribution all place the cone at the inferior pupillary margin, while the curvature display incorrectly locates the cone near the limbus.

## CONCLUSION

As newer technologies emerge, we can obtain a more comprehensive picture of the corneal anatomy. Accurate assessment of the posterior corneal surface and the pachymetric distribution adds significantly to our knowledge and should allow for better and more complete preoperative evaluations. ■

*Michael W. Belin, MD, FACS, is Professor and Director of Cornea & Refractive Surgery at Albany Medical College in New York and Medical Director of the TLC Laser Eye Center in Albany, New York. He serves as a consultant to Oculus, Inc. Dr. Belin may be reached at (518) 475-1515.*

## JACK T. HOLLADAY, MD, MSEE, FACS USING THE HOLLADAY REPORT ON THE OCULUS PENTACAM

Multiple mapping selections equal advanced preoperative detection.

The Pentacam Comprehensive Eye Scanner differs fundamentally from the Orbscan (Bausch & Lomb, Rochester, NY) by the way in which it takes image slices of the cornea. The Orbscan takes vertical image slices that are separated from one another and have no common point. Thus, the Orbscan cannot re-register for

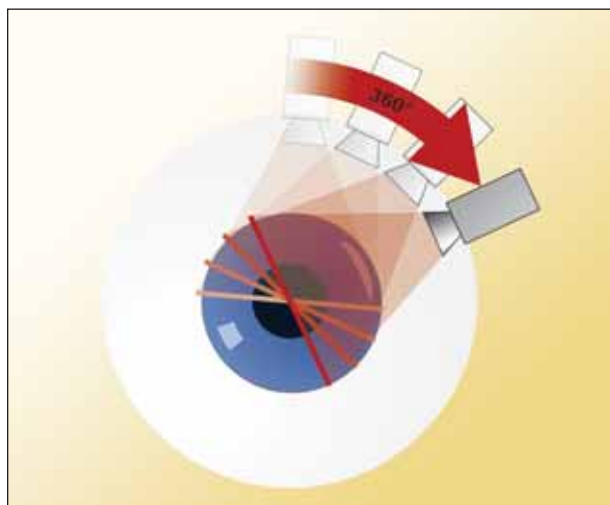


Figure 1. The Pentacam takes multiple image samples.

any eye movement that occurs while it is capturing the images. The Pentacam maintains the central point (the thinnest point) of each meridian in the sample images (Figure 1). Thus, during the examination, the software can re-register these central points and eliminate the eye movement. This single feature makes the Pentacam's measurements 10 times more accurate than the Orbscan's.

The Pentacam's density maps allow the physician to quantitate opacities. For example, the map of a cataract may show opacities that scatter light and degrade vision (Figure 2). Thus, the physician can show these maps to the patient and document the changes that are occurring to the patient's crystalline lens in his chart.

### CURVATURE MAPS

I like to include curvature maps in my preoperative screening. It is true that curvature maps are relative to the center of the earth (primary corneal radius of curvature), and that height maps are relative to a vertex point on the cornea. The Pentacam uses a sagittal drop-down map to reference a fixed physical point on the surface of the cornea for elevation maps. When using a curvature map, you calculate a radius and then determine the major center of the radius of the curvature (a calculated point). If the machine does not calculate the right point, or if the patient is not lined up, then the radius-of-curvature calculation will be off. The Pentacam has an alignment device that prevents decentration.

When performing IOL calculations, you cannot use height math to determine the power of the cornea. Corneal power is based on the height data; you must

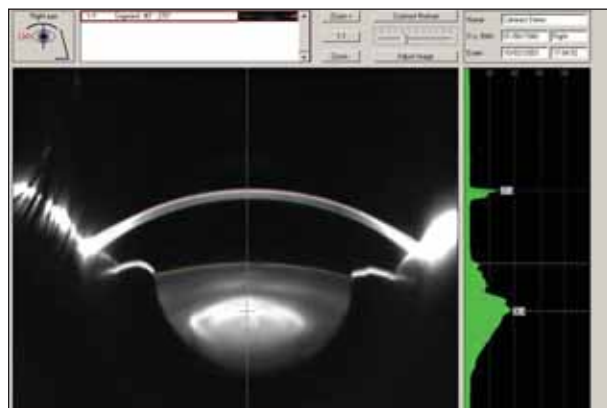


Figure 2. The density map shows lenticular opacities.

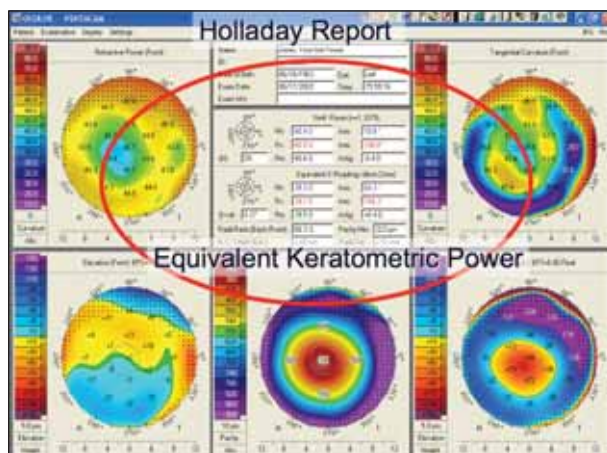


Figure 3. The Holladay Report displays five Pentacam maps.

calculate a radius. Topography does not supply back surface power. Therefore, the variation in back surface power among the human population means that K readings that may appear the same between multiple patients are not exactly the same, because their posterior curvatures and net powers are different. In order to calculate posterior curvature values, my staff and I measured 100 consecutive refractive surgery patients who were between 20 and 30 years old with the Pentacam pre- and postoperatively. Using the historical method, we were able to calculate what their K readings should have been postoperatively. The correlation was 96%, with 0.55D standard deviation. Thus, we were able to predict patients' postoperative refractive powers within 0.55D, which is much better than the historical and other methods.

### THE HOLLADAY REPORT

Because I like to look at several maps when evaluating a patient, I worked with Oculus to create the

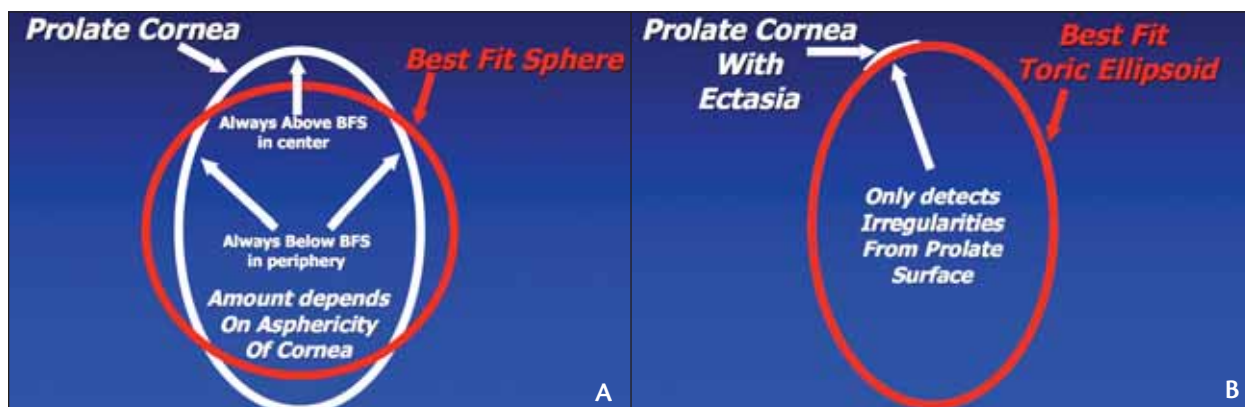


Figure 4. A best-fit sphere (A) does not align as well to a prolate cornea as a toric ellipsoid (B).

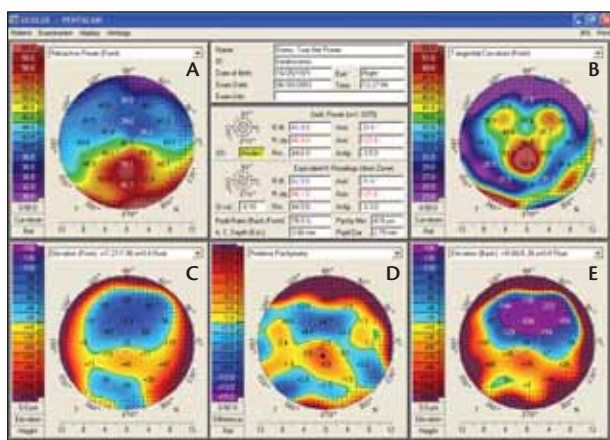


Figure 5. Advanced preoperative detection with five maps: refractive power (A); tangential (B); sagittal anterior (C); relative pachymetry (D); and elevation [posterior] (E).

Holladay Report (Figure 3). The Report uses a landscape rather than a portrait format to show a variety of information that can be printed out and placed in the chart for the physician. For example, I may want to know how the refractive power has changed over the surface of the cornea so I can correlate refractive changes with changes on the corneal surface. The refractive power map can identify whether cataract surgery has produced a decentered ablation zone. An axial power map would not show this information, but a refractive power map uses Snell's law and shows an index of refraction to calculate the power. The tangential map is also a curvature map, but is based on local radius of curvature; it is much more sensitive and detailed and therefore highlights any aberrations induced by refractive surgery.

### BEST-FIT SPHERES VERSUS ELLIPSOIDS

Most physicians who transition from the Orbscan to the Pentacam are accustomed to using a best-fit sphere

(Figure 4A), because software written for these devices during the last 15 years was formulated for this shape. The profession is now moving toward using toric ellipsoids, which make the readings much more sensitive (Figure 4B). The technique is somewhat advanced; you no longer see a band across the corneal surface as you do in an eye with astigmatism when using sphere as a reference. Using toric ellipsoids, the Pentacam generates a new map called *relative pachymetry*. This system measures the front and back corneal powers and displays what we call an *equivalent K* reading over a 4-mm zone. Let me explain further.

Every IOL formula used today reduces the K reading by 2% to compensate for the fact that the true net power of the cornea is approximately 0.75D (2%) less than the K reading. However, the Pentacam does measure true net power directly. If the true net power were input, with any of these formulas, they will reduce the calculated power by another 0.75D, thus producing 0.75D of error (double correction). The equivalent K reading boosts the IOL power's value to be comparable to the keratometer, but it also adjusts the calculation by the back surface power either positively or negatively to obtain the difference in the back power from the normal calculation that the keratometer assumes. For example, a measurement of 45.00D on the keratometer will measure 44.25D on the Pentacam's true net power. I change that to 45.00D so I have the same reading, but then I add or subtract the difference in the back surface power that was assumed by the keratometer. Most formulas assume the back surface of the cornea is 82.2% of the front surface power. If the reading is a little higher or lower, I can adjust the equivalent parametric power to utilize the precision of the Pentacam and take into account the back surface power, without needing a new A-constant for every lens available today to change it by 0.75D. This approach produces the right value for the calculation.

**MAPPING CORNEAL ECTASIA**

Corneal ectasia by definition is a thinning keratoconus. The posterior surface usually reveals the first detectable thinning, because, as the epithelium gets thinner over the anterior surface of the cone, Bowman's membrane comes forward, making the thinning undetectable on curvature and height maps. I believe that a best-fit sphere is not as sensitive as the posterior surface map, because the cornea usually is prolate and has astigmatism. The back surface is never as precise as the front, because its curvature and height are calculated by looking through the front surface of the cornea, making the back surface a virtual image.

The cornea is not a sphere, it is a football. A prolate ellipsoid shape only detects irregularities on a prolate surface. With this shape, an ectatic spot on a prolate cornea would look like a small bump on a map. Then, the tangential map, relative pachymetry map, and posterior elevation map all show the same "hot spot" point (Figure 5). A hot spot in the same location on all three maps indicates a suspicious irregularity such as a cone or corneal thinning. Thus, the information provided by these three maps equals advanced preoperative detection. The tangential map helps you look for the nipple of the aberration, the toric ellipsoid float helps you eliminate the normal elevation above the sphere so that you are looking only at the irregularity, and the relative pachymetry map directs you to the thinnest point on the cornea relative to its normal thickness. ■

*Jack T. Holladay, MD, MSEE, FACS, is Clinical Professor of Ophthalmology at Baylor College of Medicine in Houston, and he is Founder and Medical Director of the Holladay LASIK Institute in Bellaire, Texas. He is a consultant to Oculus, Inc. Dr. Holladay may be reached at (713) 668-7337; docholladay@docholladay.com.*

**MARC A. MICHELSON, MD**  
**CORNEAL ELEVATIONS, SLOPE, AND CURVATURE**

**Why topography is not enough.**

The following two cases demonstrate why I find the Pentacam Comprehensive Eye Scanner so invaluable for screening and evaluating patients for refractive surgery.

**BACKGROUND**

Corneal elevation, slope, and curvature are three different measurements. Understanding their derivation and measurements becomes extremely important

when analyzing the cornea for prospective refractive surgery.

*Corneal elevation* is the measurement of height between two different points at different elevations. Elevation data is a primary data source for the Pentacam.

*Slope* is the primary data source for Placido-disc-based technology. The slope or the gradient is commonly used to describe the measurement of the steepness, incline, or grade of a straight line from two points with different elevations. A corneal topographer derives slope data from the reflection of concentric rings of light measuring the topography of the cornea.

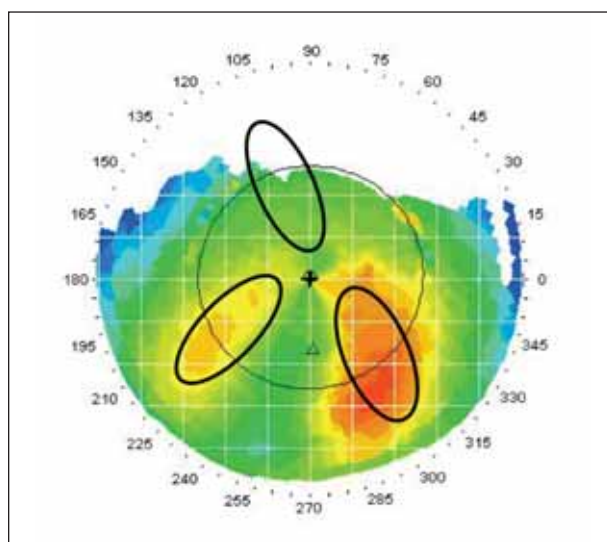


Figure 1. Nonorthogonal astigmatism on topography.

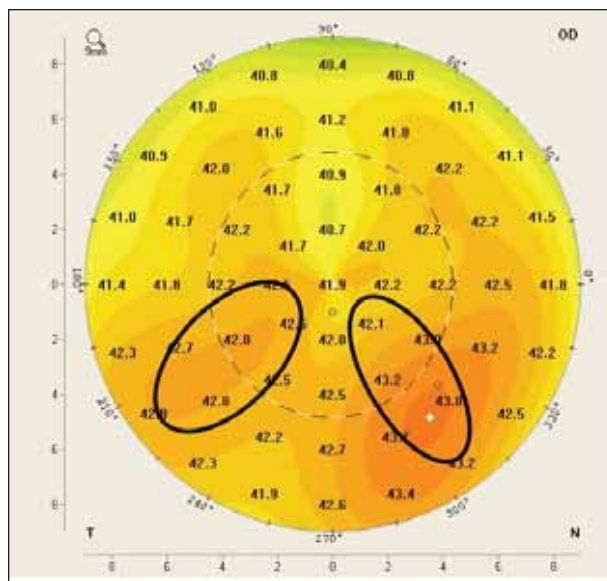


Figure 2. The Pentacam's sagittal curve front view.

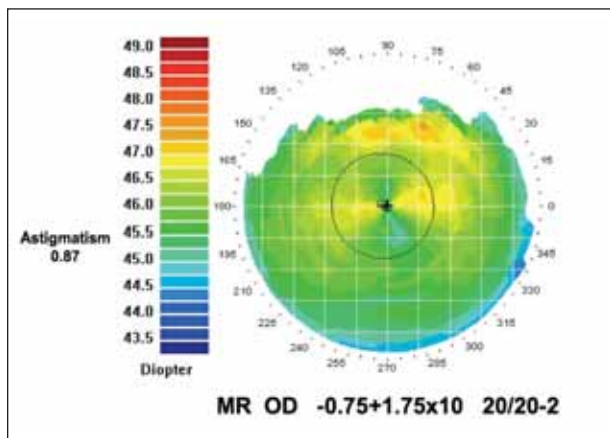


Figure 3. This topographical map looks normal.

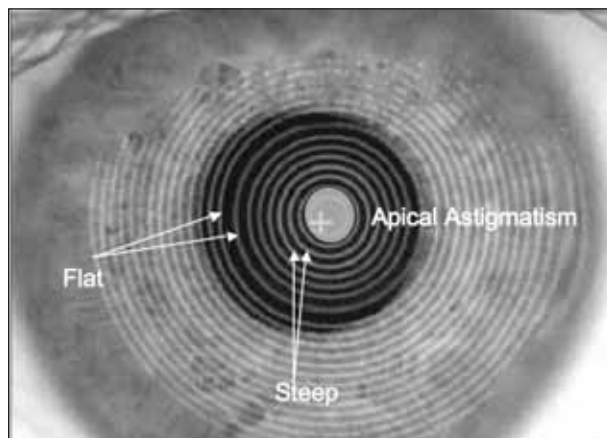


Figure 4. The photokeratoscopic image of the same eye.

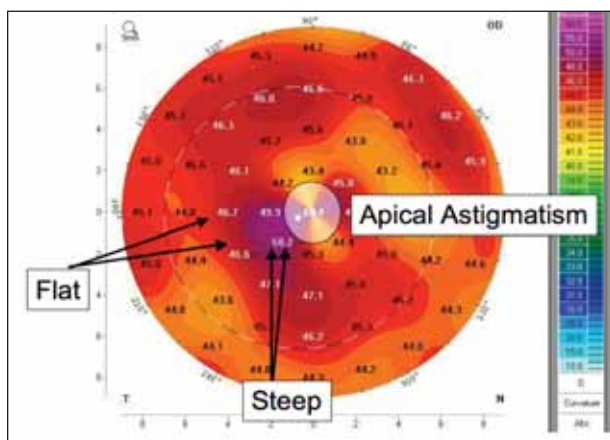


Figure 5. The eye's front sagittal curve map.

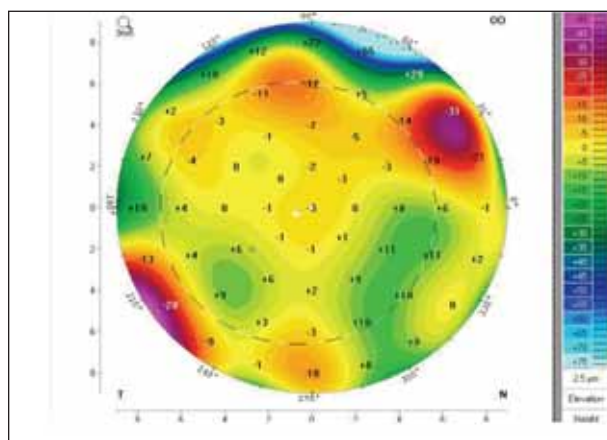


Figure 6. The eye's preoperative anterior elevation map.

Slope is the first derivative of elevation. It is then used to calculate either elevation or curvature.

*Curvature* is the rate of change of the slope. It is the second derivative of elevation and is calculated from slope data from the topography. Thus, looking at the source data, a topographer calculates the curvature and elevation from the slope, whereas the Pentacam uses elevation as its primary source data. This is an important distinction, because a topographer calculates (not measures) elevation data, and abnormal or surgically altered corneas may have multiple elevation solutions from these derived calculations. Since the Pentacam's primary data source is elevation, the first and second derivatives (slope and curvature) can be accurately calculated.

### CASE No. 1

Figure 1 shows topography from a cornea that is obviously abnormal. This eye has nonorthogonal astigmatism. The Pentacam's "sagittal curve front" view

(Figure 2) successfully mirrors the abnormal nonorthogonal corneal astigmatism as seen by topography, but the Pentacam provides much more information. Note the location of the cornea's thinnest point as well as the highest point of elevation. A posterior float of +21µm on the posterior elevation map indicates possible keratoconus. The Pentacam also has a keratoconic profile that provides indices of abnormal elevations and curvature confirming the abnormalities of this cornea.

### CASE No. 2

Figure 3 is an axial topographical map of a cornea from a 33-year-old male with a refraction of -0.75 +1.75 X 10, yielding a BCVA of 20/25. The topography appears to be normal with a typical astigmatic pattern. Figure 4 shows the photokeratoscopic Placido-disc imagery of this cornea. I think is very important to review the photokeratoscope, because it is the primary source data for the topography. First, the central rings

are oval, thus indicating astigmatism. This clearly demonstrates an apical astigmatism of the cornea. This image also shows steep areas where the rings are compressed as well as flatter areas where they are more separated. The topographic map of this cornea does not have any steep or flat areas corresponding to the steeper and flatter regions on the photokeratoscope. This information, standing alone and isolated, indicates that the patient may be a candidate for LASIK. The Pentacam, however, provides data that more closely resemble the photokeratoscope from the topographer than the axial topographic map. The system's sagittal curve front view reveals almost 6.80D of apical astigmatism at the center of his cornea. (Figure 5). There are steep areas that correspond to the contour map of the photokeratoscope of up to 50.20D, and corresponding flat areas of 46.00D: an almost a 4.00D differential within 0.50mm on the surface of the cornea. Thus, the topography accurately captured the source data from the photokeratoscopic map, but it failed to accurately compute this data to the axial topographic map, which in this case does not truly reflect the abnormalities of this cornea.

Note the interesting elevation abnormalities of the front corneal surface on the anterior elevation map (Figure 6): there is a high point elevation of +12 $\mu$ m from a best-fit sphere and also a depression of -14 $\mu$ m. The back elevation data on this eye are not unusual, but the optical pachymetric map clearly shows an abnormal pachymetry by a decentered corneal apex at the thinnest part of the cornea. The Pentacam vividly shows that this patient is not a LASIK candidate. The astigmatism in the refraction does not match that in the cornea. There are 6.80D of central astigmatism at the corneal apex and the refraction was only 1.75D of astigmatism. The kertaconic profile states that the cornea is abnormal. The K-values on the Pentacam exceed 48.00D. The Pentacam has successfully identified an abnormal cornea, when, in fact, the topography clearly did not. This case clearly has medicolegal implications. If a preoperative Pentacam analysis on this patient's eye reads abnormal, then the physician should not proceed with surgery. ■

*Marc A. Michelson, MD, is Clinical Associate Professor of Ophthalmology at the UAB Medical Center in Birmingham, Alabama, and he practices Ophthalmology at the Alabama Eye & Cataract Center, P.C., in Birmingham. He has received honoraria and reimbursement for travel for speaking on behalf of Oculus. Dr. Michelson may be reached at (205) 930-0930; marcm@alaeye.com.*

## J. TREVOR WOODHAMS, MD **PENTACAM FOR THE REFRACTIVE IOL SURGEON**

This technology is not limited to LASIK surgeons.

Over the past year, the number of lens-based refractive procedures I performed in my practice increased dramatically, whereas I used to offer cornea-based refractive surgery exclusively. This change presented my staff and I with new challenges, such as selecting candidates for LASIK. When we screen for contraindicative pathologies like keratoconus and forme fruste keratoconus, the corneal and elevation topography available on the Pentacam Comprehensive Eye Scanner are much better than Placido-based topography, especially with the new software developed by Jack Holladay, MD. Thus, the Pentacam takes the guesswork out of patient selection.

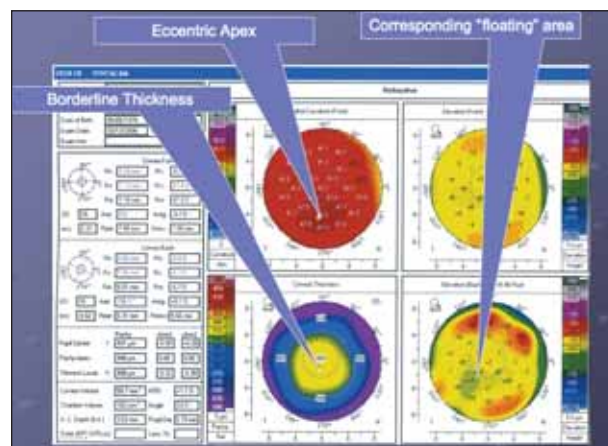


Figure 1. Pathologies identified with the Pentacam.

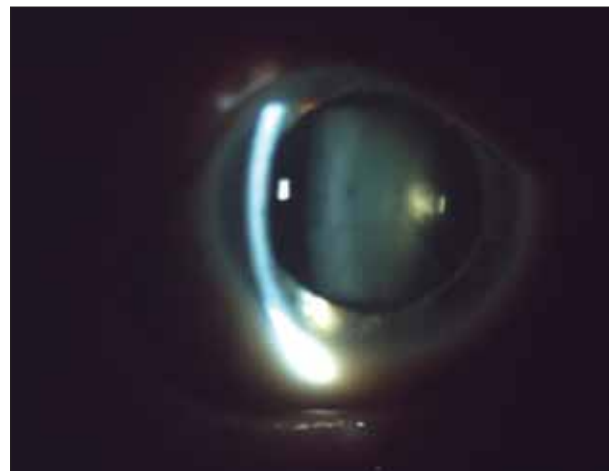


Figure 2. Is this a cataract? The Pentacam tracks progression.



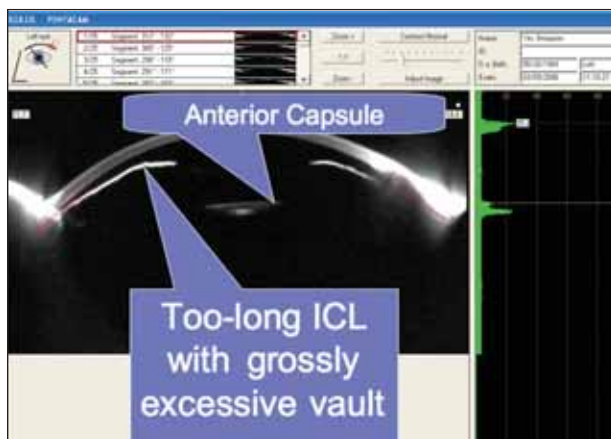


Figure 3. Scheimpflug imaging of an incorrectly sized ICL.

### CLINICAL USE

I have been using the Pentacam for about 3 years. For lenticular surgery, I use it to calculate (1) the lens thickness for the Holladay II IOL formula, (2) the anterior chamber depth for primary IOL formulas, (3) the space between the back of the cornea and the anterior lens capsule, and (4) the distance from the anterior chamber to the IOL for piggybacking. My staff and I also use the device to look for eccentric apices, corresponding float areas, and borderline abnormal corneal thicknesses (Figure 1). This technology evaluates the cornea for surgery more consistently than the Orbscan topographer (Bausch & Lomb, Rochester, NY). It also provides more information about the anterior chamber, which I believe is refractive surgery's new frontier.

### IMAGING BEHIND THE CORNEA

The Pentacam uses a bright flash (Scheimpflug photography) to take images of the exposed anterior chamber. When used through a dilated pupil, it provides the anterior chamber's depth, density, thickness, diameter, and angle measurement. These data are important because IOL implantation nomograms are still evolving. Surgeons no longer believe that white-to-white distance is an accurate measurement of the ciliary sulcus' diameter, which is an important parameter for implanting implantable contact lenses (Visian ICL; STAAR Surgical Company, Monrovia, CA) in particular.

### OTHER CLINICAL APPLICATIONS

#### Documenting and Following Pathology

The Pentacam can help the surgeon document lenticular changes in questionable eyes and track them over time. For example, does the eye in Figure 2 have a cataract? It is my eye, with 20/20 vision and modest night vision complaints. The Pentacam can track the opalescence as it develops.

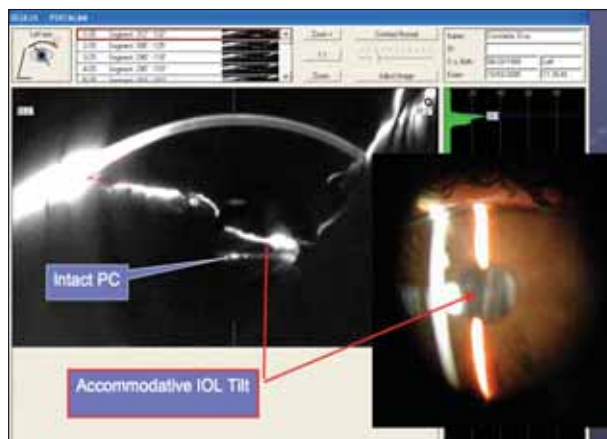


Figure 4. The tilt of an implanted accommodative IOL.

### Determining Room for an ICL

When implanting an ICL, the surgeon must determine whether the eye's angle is wide enough or deep enough for the lens to push the iris forward. Figure 3 shows a patient with too long an ICL because of poor white-to-white calculations. Note the grossly excessive vault.

### Revealing IOL Tilt

Figure 4 shows an eye implanted with a Crystalens Accommodating IOL (Eyeonics, Inc., Aliso Viejo, CA) approximately 4 years ago, when these lenses were experiencing some problems with Z syndrome. The image shows intact anterior and posterior capsules and the tilted IOL.

### Accommodative IOL Placement

I anticipate that refractive lens surgeons will find the Pentacam important for managing the capsule and selecting designs of future accommodative IOLs. We will have to know the thickness of these lenses and the depth of the posterior chamber. The Pentacam can measure true white-to-white diameters. Moreover, researchers are conducting biometric studies in order to produce an "MRI" of the eyeball and ensure the best fit for ICLs.

### Anterior Chamber Measurements for IOL Exchange

Many of my patients who underwent RK 10 years ago are now requesting enhancements, and I often implant the Crystalens. Unfortunately, these patients frequently need an IOL exchange due to power calculation difficulties. The Pentacam can get the most accurate measurement from either the anterior or posterior surface to the front of the IOL once the natural lens is removed.

### SUMMARY

In conclusion, the Pentacam's diagnostic utility is not limited to LASIK, but will also be crucial for refractive lens

procedures. The system's ability to visualize and measure the anterior segment's structures is currently unsurpassed. I look forward to the added level of accuracy that the new high-definition model will bring to this technology. ■

*J. Trevor Woodhams, MD, is Surgical Director of the Woodhams Eye Clinic in Atlanta. He acknowledged no financial interest in the products or companies mentioned herein but is reimbursed for travel expenses by Oculus, Inc. Dr. Woodhams may be reached at (770) 394-4000; TWoodhams@WoodhamsEye.com.*

### **IQBAL "IKE" K. AHMED, MD, FRCS** **PENTACAM: WHAT EVERY CATARACT SURGEON NEEDS TO KNOW**

(And benefit from.)

The advantages the Pentacam Comprehensive Eye Scanner brings to the corneal refractive surgeon are quite apparent. My colleagues and I have been using the device for more than 18 months, during which I have identified six important ways the Pentacam serves cataract surgeons.

#### **No. 1: ASTIGMATIC CORRECTION**

We have used the Pentacam's corneal topographic and thickness maps when performing limbal relaxing incisions (LRIs) or astigmatic keratotomy either intra- or postoperatively to correct astigmatism. With the current drive toward refractive precision and spectacle independence, most users now are attempting or at least considering utilizing the device's adjunctive corneal incisional treatment for cylinder as well. The system is also very helpful in identifying patients who may have irregular astigmatism. Surgeons must look for asymmetric versus symmetric cylinder and determining the appropriate incisional location and depth.

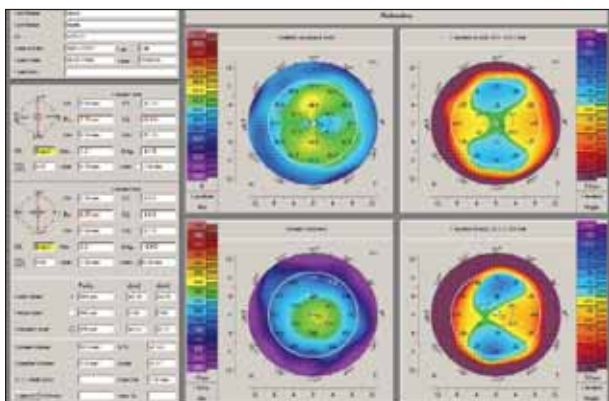


Figure 1. This eye had 4.10D of cylinder preoperatively.

Figure 1 shows a typical example of an eye that presents with a cataract and has a significant amount of astigmatic corneal cylinder. After receiving LRIs along the axis of the positive cylinder, the eye looks significantly different in the curvature maps, and its astigmatism has been reduced to around 1.50D (Figure 2). In this case, the Pentacam added value by providing curvature maps as well as corneal thickness measurements so that the surgeon could adjust the depth of the incisions. Measurements of the corneal periphery can also aid in determining the appropriate location and depth of those incisions.

Many surgeons are now using LRIs postoperatively at the slit lamp as refractive touch-ups. Safety is extremely important in this application, and here again the Pentacam's corneal thickness measurements can be useful.

#### **No. 2: COMBINING PENTACAM DATA WITH WAVEFRONT ANALYSIS**

How can we combine wavefront analysis of corneal spherical aberrations, higher-order aberrations, and spherical aberration-correcting IOLs with the measurements the Pentacam delivers? The Pentacam provides a Zernike analysis of the cornea, which is something I think will be of great value for determining the appropriate customized IOL for specific patients. Postoperative refractive targets in cases of spherical aberration is still a matter of debate: do we target zero, or else a little bit of positive spherical aberration to try to optimize the patient's contrast sensitivity? With the current Pentacam platform, this corneal spherical aberration measurement is given as a coefficient of the Zernike polynomial the system calculates. It does require third-party software to determine the desired postoperative result.

#### **No. 3: CATARACT ASSESSMENT: DENSITY, CONSISTENCY, AND THICKNESS**

The Pentacam is able to evaluate a cataract's location, density, thickness, and consistency as well as the anterior chamber's depth, width, and angle measurements (Figure 3). Ophthalmic surgeons proceeding into intraocular and cataract surgery will increasingly rely on appropriate three-dimensional assessments of the eye for surgical planning. I foresee a time when we enter cataract density measurements into a phaco machine to determine a patient's appropriate power modulation and fluidics. The device can also assess more subtle phenomena, like posterior capsular opacification and an anterior cortical or anterior subcapsular cataract.

#### **No. 4: AC DEPTH AND ANGLE MEASUREMENTS**

Knowing anterior chamber dimensions are also useful for treating ocular pathologies. For example, pseudoexfoliation patients can have a shallow chamber (as narrow as 2.5mm) that increases their risk of intraoperative complications. This

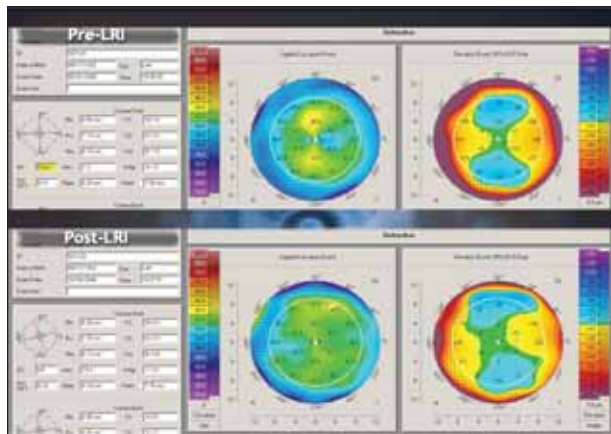


Figure 2. The eye's astigmatic cylinder was reduced to 1.50D.

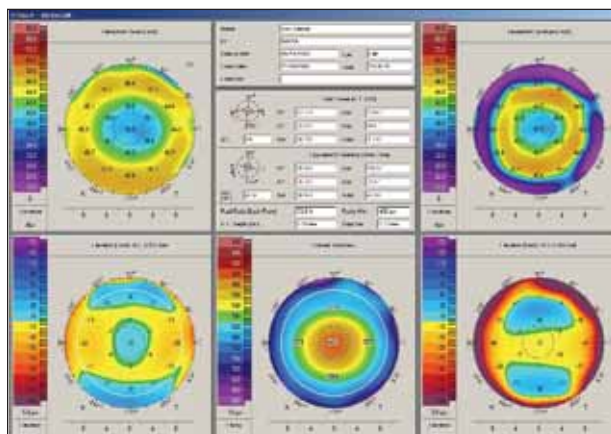


Figure 4. The post-LASIK Holladay Report for keratometry.

feature of the Pentacam can also be useful for determining angle closure and sizing anterior chamber IOLs. The system allows the surgeon to examine angle-to-angle measurements and trabecular-iris angle measurements (for patients who may be at risk for angle closure) and reconstruct a three-dimensional model of the anterior chamber.

### No. 5: PERFORMING KERATOMETRY IN THE POST-LASIK PATIENT

The Holladay II report is essential for determining keratometry for patients who have had LASIK or corneal refractive surgery (Figure 4). Because the Pentacam enables central corneal sampling compared to Placido-disc technology and also is able to determine anterior and posterior corneal curvature and thus ratio, Dr. Holladay has devised calculations to provide more accurate keratometry for IOL calculations in the post-LASIK patient.

### No. 6: IOL ASSESSMENT

The ability to postoperatively view and evaluate IOL positioning, centration, and tilt is invaluable, especially

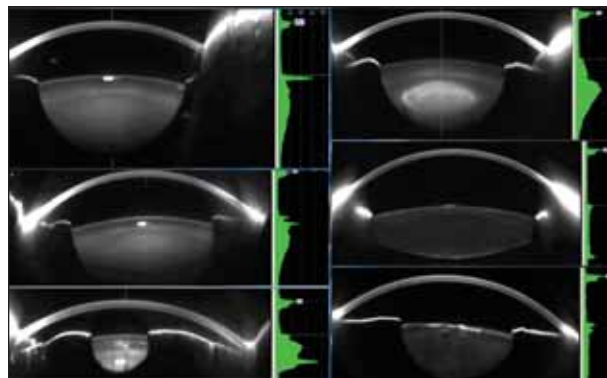


Figure 3. Different grades of cataract seen with the Pentacam.

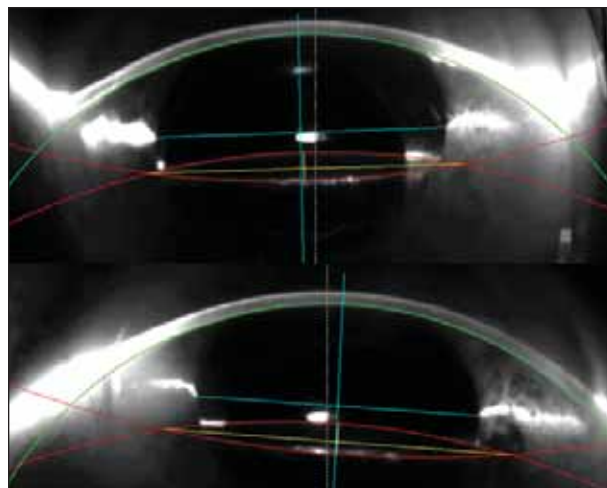


Figure 5. The Pentacam calculates best-fit curve and plane.

when a patient has not achieved the desired result or may have postoperative dysphotopsia or other visual complaints. Certain third-party software for the Pentacam can easily illustrate the outline of an IOL in most cases. It can then calculate a lens' best-fit curve and plane in comparison to the optical and geometric axes of the anterior chamber, thus allowing the physician to determine the correct positioning of the IOL (Figure 5).

### SUMMARY

I have found that the Pentacam offers significant value to the cataract surgeon as ophthalmology evolves into an era where imaging is becoming more important in all areas of the eye. ■

*Iqbal "Ike" K. Ahmed, MD, FRCSC, is Assistant Professor at the University of Toronto and Clinical Assistant Professor at the University of Utah in Salt Lake City. He is not a consultant to Oculus, Inc., and he acknowledged no financial interest in the company or its products. Dr. Ahmed may be reached at (905) 820-3937; ike.ahmed@utoronto.ca.*